

Current Canine Guidelines for the
Prevention, Diagnosis,
and Management of
Heartworm (*Dirofilaria immitis*)
Infection in Dogs



AMERICAN
HEARTWORM
SOCIETY
EST. 1974

Revised 2018

Thank You to Our Generous Sponsors:



Boehringer
Ingelheim



zoetis



IDEXX
LABORATORIES



© 2018 American Heartworm Society | PO Box 8266 | Wilmington, DE 19803-8266 | E-mail: info@heartwormsociety.org

Current Canine Guidelines for the
**Prevention, Diagnosis,
and Management of
Heartworm** (*Dirofilaria immitis*)
Infection in Dogs



(Revised 2018)

CONTENTS

Click on the links below to navigate to each section.

Preamble	3
HIGHLIGHTS	3
EPIDEMIOLOGY	4
Key Points	
Minimizing Heartworm Transmission in Relocated Dogs (box)	
Figure 1. Urban heat island profile.	
BIOLOGY AND LIFE CYCLE	7
Key Points	
Figure 2. The heartworm life cycle.	
Figure 3. Images of a feeding mosquito.	
HEARTWORM PREVENTION	9
Key Points	
Macrocyclic Lactones	
Reports of Lack of Efficacy	
Vector Control	
Measures to Reduce Heartworm Transmission (box)	
Use of Repellents and Ectoparasiticides	
Multimodal Risk Management	
PRIMARY DIAGNOSTIC SCREENING	14
Key Points	
Test Timing for Optimal Results	
Microfilaria and Antigen Testing	
Antigen Tests	
When Should Heat Treatment of Samples Be Considered? (box)	
Microfilaria Tests	
How to Perform the Knott Test (box)	
Testing Considerations Following Noncompliance and When Changing Products	
Figure 4. <i>Acanthocheilonema reconditum</i> and <i>Dirofilaria immitis</i> .	
Figure 5. The testing protocol following known noncompliance.	

Other Diagnostic Aids	17
<i>Radiography</i>	
<i>Echocardiography</i>	
<i>Figure 6. Moderate heartworm disease (radiographs).</i>	
<i>Figure 7. Severe heartworm disease (radiographs).</i>	
<i>Figure 8. Echocardiogram.</i>	
Diagnostics For Pre-Adulticide Evaluation In An Infected Dog	18
PRINCIPLES OF TREATMENT	20
<i>Key Points</i>	
<i>Table 1. Summary of Clinical Signs of Canine Heartworm Disease</i>	
<i>Figure 9. Image of the main trunk of the right pulmonary artery.</i>	
<i>Figure 10. Image of a dead adult heartworm lodged in a distal pulmonary artery.</i>	
Adulticide Therapy	21
<i>Melarsomine Dihydrochloride</i>	
<i>Pulmonary Thromboembolism</i>	
Adjunct Therapy	22
<i>Steroids</i>	
<i>NSAIDs and Aspirin</i>	
<i>Doxycycline</i>	
<i>Macrocyclic Lactones</i>	
<i>Macrocyclic Lactones/Doxycycline</i>	
<i>Figure 11. Pulmonary pathology associated with death of heartworms.</i>	
AHS-Recommended Protocol	24
<i>Table 2. AHS-Recommended Protocol</i>	
Elimination of Microfilariae	26
Surgical Extraction of Adult Heartworms	26
<i>Caval Syndrome (Dirofilarial Hemoglobinuria)</i>	
<i>Pulmonary Arterial Infections</i>	
<i>Figure 12. Photographic Image of a heart from a dog suffering from caval syndrome.</i>	
<i>Figure 13. Echocardiogram image.</i>	
<i>Figure 14. Surgical removal of worms.</i>	
Alternative Therapies	28
<i>Long-term Macrocyclic Lactone Administration</i>	
<i>Herbal Therapies</i>	
Compounded Medications	28
Confirmation of Adulticide Efficacy	28
Elective Surgeries in Dogs with Heartworms	29
REFERENCES	29

Prepared by Dr. C. Thomas Nelson, Dr. John W. McCall, Dr. Stephen Jones, and Dr. Andrew Moorhead, and approved by the Executive Board of the American Heartworm Society: Officers: Dr. Chris Rehm, President; Dr. Stephen Jones, Past President; Dr. Tony Rumschlag, Vice President; Dr. Bianca Zaffarano, Secretary-Treasurer; Dr. Patricia Payne, Editor; Dr. Doug Carithers, Symposium Program Chair; Board Members: Dr. Elizabeth Clyde, Dr. Brian DiGangi, Dr. Chris Duke, Dr. Andrew Moorhead, Dr. Charles Thomas Nelson, and Dr. Jennifer Rizzo; and Ex Officio Members: Dr. Marisa Ames, Symposium Program Co-Chair; Dr. John W. McCall, Associate Editor; Dr. Chris Adolph and Dr. Edward Wakem.

References by Christopher Evans, MS, Research Professional II, Department of Infectious Diseases, College of Veterinary Medicine, University of Georgia.

Preamble

These recommendations supersede previous editions and are based on the information presented at the 2016 Triennial Symposium of the American Heartworm Society (AHS), new research, and additional clinical experience. The recommendations for the prevention, diagnosis, and management of heartworm infection in cats are contained in a companion feline document (available on the [AHS website](#)).

HIGHLIGHTS

- **Diagnostics**

AHS recommends annual antigen and microfilaria testing. (As the interpretation of diagnostics has become more complex, please see the “Microfilaria and Antigen Testing” section for more complete information.)

- **Prevention**

AHS recommends year-round administration of preventive drugs approved by the US Food and Drug Administration (FDA) to prevent heartworm infection and enhance compliance, the latter being particularly important in light of the documented presence of resistant subpopulations. Application of an Environmental Protection Agency (EPA) registered mosquito repellent/ectoparasiticide has been shown to increase the overall efficacy of a heartworm prevention program in laboratory studies involving known resistant heartworm isolates by providing control of the arthropod vector of heartworm. In addition, AHS recommends reduction of exposure to mosquitoes through standard environmental control of mosquitoes and their breeding environments, and when possible, reducing outdoor exposure during key mosquito feeding periods.

- **Adulticide Therapy**

AHS recommends use of doxycycline and a macrocyclic lactone prior to the three-dose regimen of melarsomine (one injection of 2.5 mg/kg body weight followed at least one month later by two injections of the same dose 24 hours apart) for treatment of heartworm disease in both symptomatic and asymptomatic dogs. Any method utilizing only macrocyclic lactones as a slow-kill adulticide is not recommended.

EPIDEMIOLOGY

Heartworm infection in dogs has been diagnosed around the globe. In the United States, its territories, and protectorates, heartworm is considered at least regionally endemic in each of the contiguous 48 states, Hawaii, Puerto Rico, US Virgin Islands, and Guam (Bowman et al, 2009; Kozek et al, 1995; Ludlam et al, 1970). Heartworm transmission has not been documented in Alaska; however, there are regions in central Alaska that have mosquito vectors and climate conditions to support the transmission of heartworms for brief periods (Darsie and Ward, 2005; Slocombe et al, 1995; Terrell, 1998). Thus, the introduction of microfilaremic dogs or wild canids could set up a nidus of infection for local transmission of heartworm in this state (see box on page 5 for more on the role of transport of infected dogs). Such relocation of microfilaremic dogs and expansion of the territories of microfilaremic wild canids in other areas of the United States continue to be important factors contributing to further dissemination of the parasite, as the ubiquitous presence of one or more species of vector-competent mosquitoes makes transmission possible wherever a reservoir of infection and favorable climatic conditions co-exist. Change in any of these factors can have a significant effect on the transmission potential in a specific geographic location.

Environmental and climatic changes, both natural and those created by humans, and animal movement have increased heartworm infection potential. Commercial and residential real estate development of non-endemic areas and areas of low incidence has led to the resultant spread and increased prevalence of heartworms by altering drainage of undeveloped land and by providing water sources in new urban home sites. In the western United States, irrigation and planting of trees has expanded the habitat for *Aedes sierrensis* (western treehole mosquito), the primary vector for transmission of heartworms in those states (Scoles et al, 1993, 1995).

Aedes albopictus (Asian tiger mosquito), which was introduced into the Port of Houston in 1985, has now spread northward and eastward, approaching Canada, and isolated populations have been identified in areas in the western states. This urban-dwelling mosquito is able to reproduce in small containers, such as flowerpots (Benedict et al, 2007).

KEY POINTS: EPIDEMIOLOGY

- Heartworm infection has been diagnosed in all 50 states and around the globe.
- Environmental and climatic changes, both natural and those created by humans, relocation of microfilaremic dogs, and expansion of the territories of microfilaremic wild canids continue to be important factors contributing to further spread of the parasite.
- A pivotal prerequisite for heartworm transmission is a climate that provides adequate temperature and humidity to support a viable mosquito population, and can also sustain sufficient heat to allow maturation of ingested microfilariae into infective, third-stage larvae (L3) within the intermediate host.
- The length of the heartworm transmission season in the temperate latitudes also depends on factors such as the influence of microclimates, unique biological habits and adaptations of the mosquito vector, variations in time of larval development, mosquito life expectancy, and temperature fluctuations.
- Heartworm transmission does decrease in winter months, but the presence of microenvironments in urban areas suggests that the risk of heartworm transmission never reaches zero.

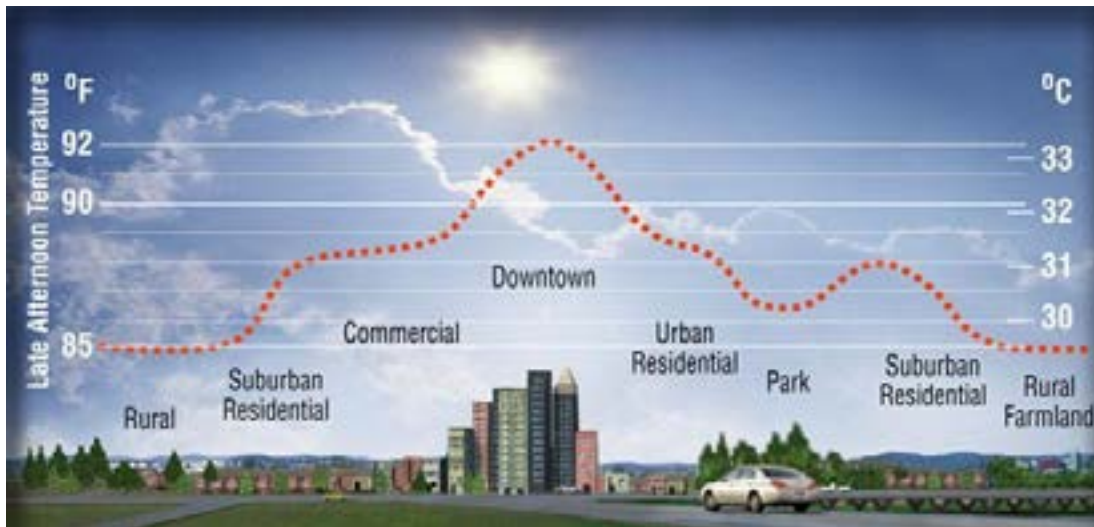


Figure 1. Urban heat island profile showing the elevation in urban air temperature compared with rural air temperature. (Image courtesy of Heat Island Group, Lawrence Berkeley National Laboratory).

Urban sprawl has led to the formation of “heat islands,” as buildings and parking lots retain heat during the day (**Figure 1**), creating microenvironments with potential to support the development of heartworm larvae in mosquito vectors during colder months, thereby lengthening the transmission season (Morchón et al, 2012, Nelson, 2016).

As mosquito vectors expand their territory and new non-native vectors are introduced (e.g., *Aedes notoscriptus* introduction to California; Peterson and Campbell, 2015) the number of animals infected will continue to increase. A pivotal prerequisite for heartworm transmission is a climate that provides adequate temperature and humidity to support a viable mosquito population, and can also sustain sufficient heat to allow maturation of ingested microfilariae into the infective, third-stage larvae (L3) within this intermediate host. It has been shown in three mosquito species that maturation of larvae ceases at temperatures below 57°F (14°C) (Christensen and Hollander, 1978; Fortin and Slocombe, 1981). Heartworm transmission does decrease in winter months, but the presence of microenvironments in urban areas suggests that the risk of heartworm transmission never reaches zero (Nelson, 2016). Furthermore, some species of mosquitoes overwinter as adults. While heartworm larval development in these mosquitoes may cease in cool temperatures, development quickly resumes with subsequent warming (Christensen and Hollander, 1978; Ernst and Slocombe, 1983).

The length of the heartworm transmission season in the temperate latitudes is critically dependent on the accumulation of sufficient heat to incubate larvae to the infective stage in the mosquito (Knight and Lok, 1998 ; Lok and Knight, 1998). The peak months for heartworm transmission in the Northern Hemisphere are typically July and August. Models predict that heartworm transmission in the continental United States is limited to 6 months or less above the 37th parallel at approximately the Virginia–North Carolina

Minimizing Heartworm Transmission in Relocated Dogs

Transporting and relocating dogs is an increasingly common practice. Whether the situation is an owned pet accompanying emigrating or traveling caretakers, the relocation of homeless animals for adoption, or the movement of dogs for competition, exhibition, research or sale, this process carries the risk of spreading infectious diseases. This includes the transmission of *Dirofilaria immitis* when infected dogs are microfilaremic.

The American Heartworm Society, in collaboration with the Association of Shelter Veterinarians, has developed a protocol to help minimize the risk of heartworm transmission associated with transportation and relocation of dogs. The document, which includes an [algorithm](#) outlining testing and treatment recommendations, is available on the AHS website.

state line (Guerrero et al, 2004).

While model-based predictions of transmission using climatic data are academically appealing, they typically fail to consider several potentially important factors, such as influence of microclimate, unique biological habits and adaptations of the mosquito vector, variations in time of larval development, mosquito life expectancy, and temperature fluctuations. Predictive risk maps assume that mosquito vectors live for only one month; however, several significant mosquito vectors live and breed for much longer periods, including:

- *Aedes albopictus* (3 months) (Löwenberg-Neto and Navarro-Silva, 2004),
- *Aedes sticticus* (3 months) (Gjullin et al, 1950),
- *Ochlerotatus* (formerly *Aedes*) *trivittatus* (2 months) (Christensen and Rowley, 1978),
- *Aedes vexans* (2 months) (Gjullin et al, 1950), and
- *Ochlerotatus* (formerly *Aedes*) *canadensis* (several months) (Pratt and Moore, 1960).

There are also documented cases of hibernating

Anopheles quadrimaculatus surviving for 4 to 5 months (Hinman and Hurlbut, 1940), so the predictive risk maps likely reflect a shorter transmission season than actually exists in some areas.

Survey studies of trapped mosquitoes randomly collected at various locations have demonstrated heartworm infection rates in mosquitoes ranging from 2% to 19.4% in known endemic areas. When mosquito sampling was restricted to kennel structures where known positive dogs were being housed, the infection rates of the mosquitoes in these restricted samplings resulted in rates of 30% adjacent to and 74% inside the facilities (McKay et al, 2013). Based upon these data, it is important to protect pets from mosquito exposure (see **Vector Control** starting on page 11) in addition to administering year-round heartworm preventive.

Once a reservoir of microfilaremic domestic and wild canids is established beyond the reach of veterinary care, the ubiquitous presence of one or more species of vector-competent mosquitoes makes transmission possible and eradication improbable.

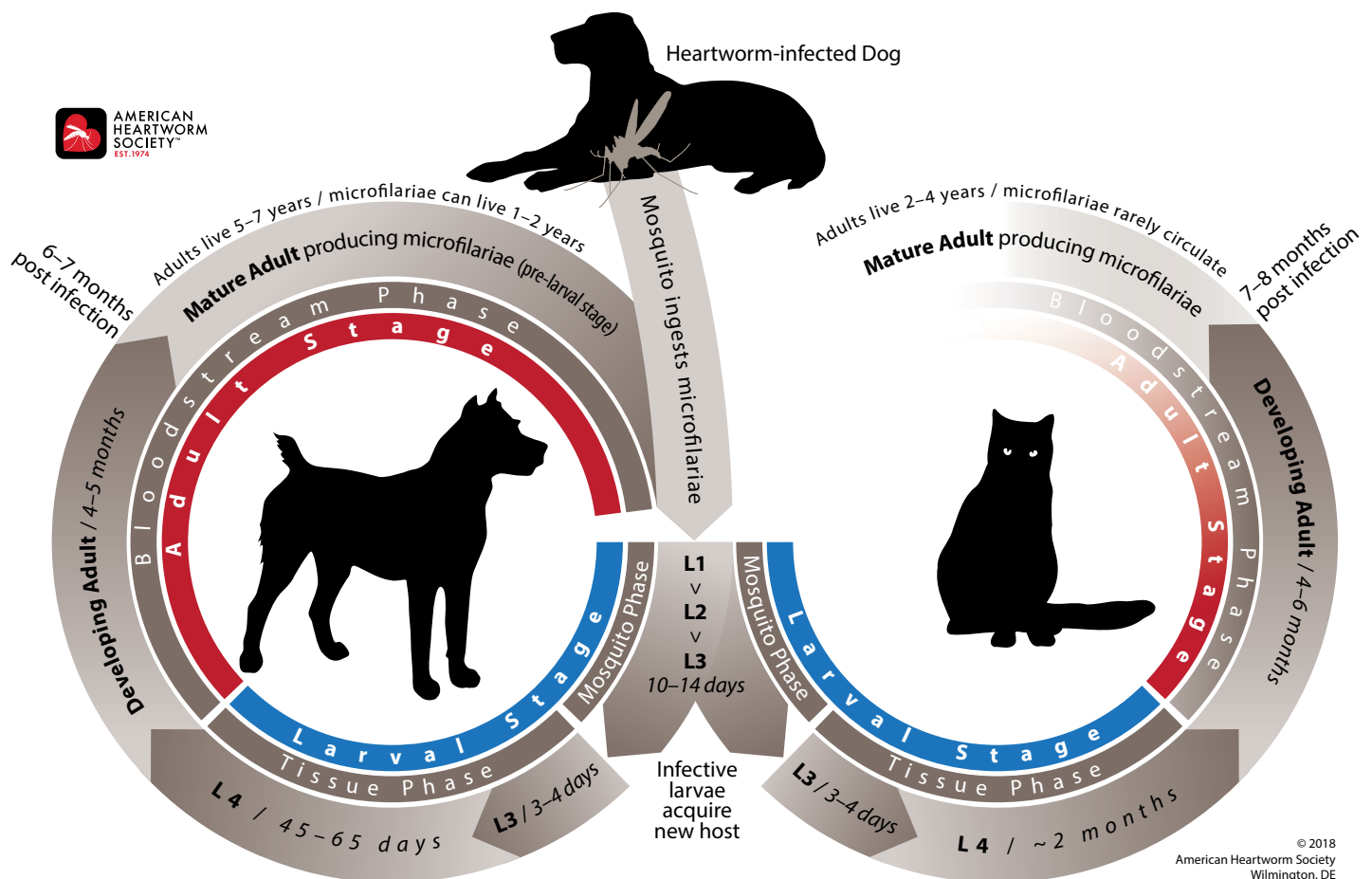


Figure 2. The heartworm life cycle.

BIOLOGY AND LIFE CYCLE

The life cycle of *Dirofilaria immitis* is relatively long (usually 7 to 9 months) compared with most parasitic nematodes (Kotani and Powers, 1982) (**Figure 2**). This protracted life cycle requires a reservoir of infection, a vector capable of transmitting infection, and a susceptible host.

The domestic dog and some wild canids are the normal definitive hosts for heartworms and are inclined to develop high microfilaria counts, thus allowing them to serve as the main reservoir of infection. Less suitable hosts, such as cats and ferrets, occasionally have low-level, transient microfilaremia and theoretically may serve as a limited source of infection for mosquitoes during their short periods of microfilaremia (McCall et al, 2008b).

The mosquito, the required vector for transmission of *D. immitis*, becomes infected as she takes a blood meal from a microfilaremic host. It is important to note that microfilariae cannot develop into adult heartworms without first developing into larval stage 1 (L1) in the malpighian tubules of the mosquito, then molting into larval stage 2 (L2), and finally molting into third-stage larvae (L3) (Taylor, 1960). The third-stage larvae, the infective stage, then migrate via the body cavity to the head and mouthparts of the mosquito, where they are positioned for transmission. The time required for the development of microfilariae to the infective stage within the mosquito is temperature dependent. At 27°C (80.6°F) and 80% relative humidity, development takes about 10 to 14 days; with cooler temperatures maturation takes longer (Kartman, 1953; Slocombe et al, 1989).

Once in the mouth parts, transmission of the infective L3 is accomplished when an infected mosquito again takes a blood meal. As the mosquito's stylet penetrates an animal's skin, the labium (lower lip) is forced to fold back at a dramatic angle (**Figure 3**). When this occurs, the tip of the labium ruptures expelling a droplet of hemolymph containing infective larvae onto the surface of the host's skin (McGreevy et al, 1974).

Immediately after the blood meal, these sexually differentiated larvae enter the animal's body via the puncture wound made by the mosquito. As early as day 3, and by days 9 to 12, the L3 molt into fourth-stage larvae (L4) where they appear to travel between subcutaneous tissues and muscle

KEY POINTS: BIOLOGY AND LIFE CYCLE

- The relatively long life cycle of *D. immitis* (7 to 9 months) requires a reservoir of infection, a vector capable of transmitting infection, and a susceptible host.
- The mosquito, the required vector for transmission of *D. immitis*, becomes infected as she takes a blood meal from a microfilaremic host.
- The *D. immitis* microfilariae mature within the malpighian tubules of the mosquito, developing into larval stage 1 (L1), then molting into larval stage 2 (L2), and finally molting into the infective third-stage larvae (L3), which are transmitted to the dog when bitten by the mosquito.
- Once the infective L3 enter the dog's body, they molt into fourth-stage larvae (L4).
- A final molt into juvenile/immature adults occurs between days 50 and 70, while they are migrating through the body; and they eventually reach the smallest pulmonary arteries as early as day 67 after transmission.
- Sexual maturity occurs about day 120 post infection with dogs developing patent infections (i.e., having circulating microfilariae) as early as 6 months but usually by 7 to 9 months after infection.
- A clear understanding of heartworm transmission, development, prepatent period, and the susceptibility of the different life stages of the parasite to available pharmaceutical drugs is critical to the successful management of infected dogs.




Figure 3. Left, Image of a feeding mosquito indicating how deeply the stylet (S) penetrates the skin and the dramatic folding (*black arrow*) of the labium (L). Right, Magnified image of a feeding mosquito indicating the release of a hemolymph pool (*white arrows*) containing infective heartworm larvae (L3). Photographic images courtesy of Stephen Jones, DVM.

fibers during migration within the infected animal. A final molt into juvenile/immature adults occurs between days 50 and 70, while they migrate through the body, eventually enter the circulatory system, and are transported toward the heart and lungs (Kotani and Powers, 1982; Kume and Itagaki, 1955; Lichtenfels et al, 1985). These immature adults reach the pulmonary vasculature as early as day 67 and all have arrived by days 90 to 120.

At the time of arrival in the pulmonary arteries, these immature heartworms measure between 1 and 1.5 inches in length. As they mature, female

heartworms ultimately grow tenfold to reach 10 to 12 inches in length. Sexual maturity occurs about day 120 post infection with dogs developing patent infections (i.e., having circulating microfilariae) as early as 6 months but usually by 7 to 9 months after infection (Kotani and Powers, 1982; Orihel, 1961).

When juvenile heartworms first arrive in the lungs the flow of blood forces them into the small pulmonary arteries (Rawlings, 1980). As the worms increase in size, they progressively occupy larger and larger arteries until they become fully mature. The eventual location of the mature adult worm appears to depend mainly on the size of the dog and the worm burden. A medium-sized dog (e.g., Beagle) with a low worm burden (≤ 5) usually has worms mainly in the lobar arteries and main pulmonary artery. As the worm burden increases, worms also can be located in the right ventricle. Dogs with more than 40 worms are more likely to develop caval syndrome, where the worms maneuver into the right ventricle, right atrium, and the vena cava, thus interfering with valvular function and blood flow and producing hemolysis, liver and kidney dysfunction, and heart failure (Atwell and Buoro, 1988; Ishihara et al, 1978; Jackson, 1975).

A clear understanding of heartworm transmission, development, prepatent period, and the susceptibility of the different life stages of the parasite to available pharmaceutical drugs is critical to be able to effectively select the most appropriate adulticidal treatment option and treatment time, and to convey realistic expectations to the client for the outcome of therapy.

A clear understanding of heartworm transmission, development, prepatent period, and the susceptibility of the different life stages of the parasite to available pharmaceutical drugs is critical to be able to effectively select the most appropriate adulticidal treatment option and treatment time, and to convey realistic expectations to the client for the outcome of therapy.

HEARTWORM PREVENTION

The prescription and administration of heartworm preventive medication requires authorization by a licensed veterinarian having a valid relationship with the client and patient. To establish this relationship, heartworm prevention must be discussed with the client. If records of past treatment and testing do not exist, it is necessary to test the patient before dispensing or prescribing preventive. Options for effective preventive include several drugs administered monthly either orally or topically, or parenterally at 6-month intervals.

Heartworm disease is preventable despite the dog's inherently high susceptibility. Because all dogs living in heartworm-endemic areas are at risk, preventive medications are a high priority. Puppies should be started on prevention consisting of a macrocyclic lactone as early as possible, no later than 8 weeks of age. In highly endemic regions the addition of a mosquito repellent/ectoparasiticide is warranted. Puppies started on a heartworm preventive after 8 weeks of age should be tested 6 months after the initial dose and annually thereafter. Before initiating a preventive regimen in older dogs (7 months of age or older), antigen and microfilaria testing should be performed (see PRIMARY DIAGNOSTIC SCREENING). This practice avoids delays in detecting subclinical infections and the potential confusion concerning effectiveness of the prevention program if a pre-existing infection becomes evident after beginning preventive (e.g., preventive initiated during the prepatent period).

Even though continuous, year-round transmission may not occur throughout the country, the administration of broad-spectrum preventive products with endoparasitic and/or ectoparasitic activity for 12 months each year likely enhances compliance and may assist in preventing other pathogenic and/or zoonotic parasitic infections.

Macrocyclic Lactones

The FDA-approved heartworm preventives currently marketed (ivermectin, milbemycin oxime, moxidectin, and selamectin) belong to the macrocyclic lactone (ML) class of drugs and likely work in concert with the dog's immune system to kill susceptible larval stages (Campbell 1989, Moreno et al 2010, Vatta et al, 2014). These drugs affect microfilariae, third- and fourth-stage larvae, and in some instances of continuous use, juvenile

KEY POINTS: HEARTWORM PREVENTION

- The FDA-approved heartworm preventives currently marketed (ivermectin, milbemycin oxime, moxidectin, and selamectin) belong to the macrocyclic lactone (ML) class of drugs.
- Macrocyclic lactones, when given according to label instructions, are highly effective and are among the safest medications used in veterinary medicine.
- It is possible for an animal to become infected because of skipped or delayed administration of just one preventive dose, particularly in highly endemic areas.
- While the vast majority of reported claims of lack of efficacy of macrocyclic lactones can be linked to poor compliance, isolated pockets of resistant heartworm subpopulations have been documented, mainly in the southeastern US.
- AHS and the FDA recommend year-round administration of FDA-approved preventive drugs to prevent heartworm infection and enhance compliance.
- Application of an EPA-registered mosquito repellent/ectoparasiticide has been shown to increase the overall efficacy of a heartworm prevention program by controlling the mosquito vector in laboratory studies.
- In addition, reduction of exposure to mosquitoes through standard environmental control of mosquitoes and their breeding environments, and when possible, reducing outdoor exposure during key mosquito feeding periods is recommended.

and adult heartworms (McCall et al, 2001a, 2008b). Because their filaricidal effect on precardiac (migrating) larvae can be achieved by brief pulsing at very low doses (e.g., monthly) or continuous release of small amounts over long periods (e.g., six months), they have excellent therapeutic/toxic ratios. Macrocyclic lactones, when given according to label instructions, are highly effective and are among the safest medications used in veterinary medicine.

All orally and topically administered macrocyclic lactone preventive products are labeled for a 30-day dosing interval. Beyond this interval efficacy against late fourth-stage larvae declines and is unpredictable (Paul et al, 1986). Juvenile worms, which can be found as early as 52 days post infection, are even less susceptible to the effects of preventives. As worms age, they require progressively longer-term administration to achieve a high level of protection (McCall, 2005; McCall et al, 2001). Therefore, continuous, year-round administration of heartworm preventive is a partial safeguard in the event of inadvertent delay or omission of regularly scheduled doses.

Macrocyclic lactones, when given according to label instructions, are highly effective and are among the safest medications used in veterinary medicine.

Some Collies and other P glycoprotein-deficient dogs that have the MDR 1 mutation are unusually sensitive to a variety of commonly used veterinary drugs, including some antidepressants, antimicrobial agents, opioids, immunosuppressants, and cardiac drugs (Mealey, 2008). (For more information on drugs that cause problems in dogs with the MDR 1 mutation visit <http://vcpl.vetmed.wsu.edu/problem-drugs>.) The macrocyclic lactones are also included in this list with toxicities being reported with overdosing or in combination with other P-glycoprotein-inhibiting drugs (Pulliam et al, 1985). These intoxications have occurred most often when concentrated livestock preparations of macrocyclic lactones are either accidentally ingested

or overdosed because of human error in dosage calculation. This practice is an unjustified extra-label drug use and is discouraged. The standard preventive dosages of all macrocyclic lactones have been shown to be safe in all breeds.

Macrocyclic lactones can be administered by three routes:

- **Oral administration:** Ivermectin and milbemycin oxime are available for monthly oral administration. Some formulations are flavored and chewable to increase patient acceptance and facilitate administration. Dose units are packaged for dogs within prescribed weight ranges. **To be maximally effective, heartworm prophylaxis should be given year-round**, but if seasonal treatment is chosen, administration should begin at least one month prior to the anticipated start of heartworm transmission and, depending on the product used, may need to be continued for up to 6 months after transmission typically ceases to meet label requirements for some products (see section on Lack of Efficacy).
- **Topical administration:** Moxidectin and selamectin are available as topically applied liquid formulations. The parameters for treatment with topical products are the same as for monthly oral preventive.
- **Parenteral administration:** A single dose of the slow-release (SR) formulation of subcutaneously injected moxidectin-impregnated lipid microspheres provides continuous protection for 6 months, with the potential to enhance compliance. Administration every 6 months is necessary for maximal protection.

Reports of Lack of Efficacy

Lack of efficacy (LOE) of a heartworm preventive product is considered by the FDA's Center for Veterinary Medicine (CVM) to be a treated dog testing positive for heartworm regardless of appropriateness of dosage or administration consistency. Possible reasons for reports of LOE include:

- Failure to administer sufficient preventive,
- Failure to administer the preventive at the proper time,
- Failure of a dog to retain a dose and failure of expected absorption of the active ingredient,
- Biological variation between hosts in drug

metabolism and immune response, and in parasite susceptibility to the drug.

Thus, the exact cause of a specific reported LOE can be difficult or impossible to determine.

Fortunately, most LOE claims can be explained by compliance failure, either between the clinic and the client or the client and the pet, rather than product failure. It is possible for an animal to become infected because of skipped or delayed administration of just one preventive dose, particularly in highly endemic areas. Such areas typically have warm temperatures most of the year, an abundance of standing water, and substantial mosquito populations. These endemic areas also have large populations of infected dogs and wild canids providing a reservoir of infection.

Research is ongoing to determine the reasons for LOE. Every new study adds to our knowledge base and increases our understanding but also produces new questions. The complex biology of the parasite, the effect of changing environmental conditions that affect vector populations, the dynamics of host (wild and domestic) populations, and even the dynamics of human interactions with pets are also relevant. In the face of the many variable factors, it is critical that all members of the veterinary practice ensure that clients understand the risk and implications of heartworm infection in their area, and that they are providing appropriate year-round heartworm prevention for their pets. The macrocyclic lactones continue to be the only FDA-approved option for

It is possible for an animal to become infected because of skipped or delayed administration of just one preventive dose, particularly in highly endemic areas. Such areas typically have warm temperatures most of the year, an abundance of standing water, and substantial mosquito populations.

preventing heartworm infection and efforts need to be intensified to increase the number of dogs receiving preventive and to increase the number of doses administered per year. Reminder systems should be implemented to assist pet owners in purchasing and administering products in a timely manner.

It is now generally accepted that isolated instances of resistant heartworms have been identified. The extent, the degree of spread, and the reasons for resistance are not well understood and are controversial. Although an [algorithm](#) utilizing the microfilarial suppression test (MFST) to help clinicians evaluate cases of suspected resistance to macrocyclic lactones was recently developed (Moorhead et al, 2017), no definitive test for resistance exists, making determination of its distribution difficult. The data suggest that owner compliance is the biggest factor in the “failure” of preventives (Atkins et al, 2014). There is general agreement that resistance to experimental infections is concerning, and that the products now available are highly effective and should continue to be used as the manufacturers suggest.

Vector Control

Heartworm disease has the greatest morbidity and mortality of any vector-borne disease affecting dogs in the United States, and despite the excellent products available to prevent heartworm disease in dogs, the range and number of cases grows annually. Because the mosquito is an obligate intermediate host and vector for heartworms, the opportunity to interrupt the chain of transmission at the level of the vector should not be ignored by the pet owner, the veterinarian, or the local municipalities responsible for environmental health-mosquito abatement. A multimodal approach to address both heartworm transmission and infection needs to be considered as an important opportunity to improve outcomes for both individual dogs and the population at large. There are many examples both in veterinary and human medicine where individual and community based multimodal approaches to vector-borne disease control are strongly advocated, if not the standard of care. Examples are Lyme borreliosis in dogs and malaria in humans.

Several tactical approaches can be employed to support the overall strategy of vector control. Vector biology has been addressed elsewhere

in these guidelines. The first community-based approach should be elimination of mosquito larval habitats like standing water sources wherever possible or treatment of these habitats with chemical and biological tools such as, but not limited to, insect growth regulators, *Bacillus* species, and mosquitofish. Local application of insecticidal sprays and fogs and deployment of adult mosquito traps are other approaches. Low winds greatly disturb internally directed flight patterns of mosquitoes, and fan-generated wind has been shown to dilute attractants like carbon dioxide and is a practical approach to protecting people and pets in back yard settings (Hoffman et al, 2003). Public municipal organizations as well as private professional businesses can provide expert guidance and tools for these efforts.

Direct protective measures that can be recommended to the dog owner include risk-behavior modification such as limiting outdoor activities during peak mosquito feeding times and avoidance of known mosquito habitats. A highly effective direct protective measure is the use of topically applied ectoparasiticide products with demonstrated mosquito repellency and insecticidal claims.

Use of Repellents and Ectoparasiticides

Repellents work by inhibiting blood-feeding by vector mosquitoes and the associated transmission of infective heartworm larvae to the treated dog or microfilariae to mosquitoes. This decreases the likelihood of an uninfected dog becoming infected, or a microfilaremic dog from serving as a reservoir for infecting mosquitoes and subsequently infecting other pets. A repellent was demonstrated to be highly effective (>95%) in preventing mosquito feeding in two well-controlled laboratory studies. When treated microfilaremic dogs were challenged with uninfected mosquitoes, a repellent was 95% effective in preventing heartworm infection in the mosquito as compared with the control group (McCall et al, 2017a). These initial study results are encouraging but additional studies are needed to determine outcomes under field conditions.

Ectoparasiticides work by killing mosquitoes that have contacted or fed on a treated animal. Because mosquitoes die within 3 days following exposure to treated dogs, they are incapable of transmitting heartworms. This, in essence, renders the treated dog a non-reservoir, and as an added benefit kills the female mosquito, therefore preventing egg

laying, and ultimately reducing the local mosquito population with further reduction in heartworm transmission in the area.

While repellents and ectoparasiticides alone or together are helpful, they are not completely effective as monotherapy for heartworm prevention in highly endemic areas. In a recent study using a repellent-ectoparasiticide along with a macrocyclic lactone, however, dogs challenged with mosquitoes carrying a highly ML resistant strain of heartworm were 100% protected from infection (McCall et al, 2017b). Thus, a macrocyclic lactone preventive, concurrent with the use of a topical mosquito repellent-ectoparasiticide, may provide more complete protection from resistant as well as susceptible heartworms.

Multimodal Risk Management

The risk management approach for heartworm disease in dogs is a process of qualitatively and quantitatively evaluating the threat of infection and disease followed by coordinated and reasonable application of countermeasures to mitigate each of those threats. The threat of heartworm infection can be readily assessed from the AHS Incidence Maps (heartwormsociety.org) and from information provided elsewhere in these Guidelines.

Veterinarians should be encouraged to make recommendations for heartworm infection and disease countermeasures that are commensurate

Vector Control Measures to Reduce Heartworm Transmission

- Eliminate sources of standing water where mosquitoes can breed.
- If standing water cannot be eliminated, it should be treated with chemical and/or biological tools such as insect growth regulators, *Bacillus* species, and mosquitofish.
- Utilize local application of insecticidal sprays/fogs and adult mosquito traps.
- Reduce exposure of dogs by limiting outdoor activities during peak mosquito feeding times (dusk and dawn) and avoiding known mosquito habitats.
- Use topical ectoparasiticide products with demonstrated mosquito repellency and insecticidal claims.

The risk management approach for heartworm disease in dogs is a process of qualitatively and quantitatively evaluating the threat of infection and disease followed by coordinated and reasonable application of countermeasures to mitigate each of those threats. The threat of heartworm infection can be readily assessed from the AHS Incidence Maps (heartwormsociety.org).

with the known level of threat. For example, a dog residing in an area of low incidence may be administered a macrocyclic lactone product as a reasonable year-round countermeasure. As the threat increases, the application of a topical ectoparasiticide product having demonstrated mosquito repellency and insecticidal claims during the months of highest mosquito activity is a reasonable addition to the year-round macrocyclic lactone. For dogs residing in areas of the country where the threat is highest and sustained, the best recommendation to counter the threat of heartworm infection is year-round use of both a macrocyclic lactone and a topical ectoparasiticide product with demonstrated mosquito repellency and insecticidal claims, in addition to ensuring environmental mosquito abatement measures are taken.

Using a multimodal risk-management approach to address the threat of heartworm infection and disease enhances the potential to break the cycle of heartworm transmission, addresses the challenges of resistant phenotypes in the heartworm population, and benefits both the individual dog as well as the population at risk.

KEY POINTS: PRIMARY DIAGNOSTIC SCREENING

- The American Heartworm Society recommends annual screening for all dogs over 7 months of age with both an antigen and a microfilaria test.
- The current generation of heartworm antigen tests identifies most “occult” (adult worms present but no circulating microfilariae) infections consisting of at least one mature female worm and are nearly 100% specific. Differences in sensitivity exist especially in cases with low worm burdens and/or low antigenemia. Currently there are no verified tests capable of detecting infections consisting of only adult male worms.
- All positive antigen tests should be confirmed through additional testing prior to the administration of any therapy. Confirmation is accomplished upon the identification of circulating microfilariae, or when another positive result is obtained utilizing a different type of antigen test.
- A negative antigen test result does not confirm that a dog is free of heartworm infection; it simply indicates that no antigen can be detected by that particular testing method.
- All dogs should be tested for microfilariae. Microfilaremia validates serologic results, identifies the patient as a reservoir of infection, and alerts the veterinarian to a high microfilariae burden.
- Heat treatment of serum samples prior to heartworm antigen tests to release blocked antigen is currently available through reference laboratories. However the routine heating of blood samples IS NOT PRESENTLY RECOMMENDED for heartworm screening.
- In cases of noncompliance or changing the brand or type of heartworm preventive, the dog should be antigen and microfilaria tested prior to starting or changing products.

PRIMARY DIAGNOSTIC SCREENING

Annual testing is an integral part of ensuring that prophylaxis is achieved and maintained. Should an infection be diagnosed, more timely treatment can be provided to minimize pathology

Test Timing for Optimal Results

Currently available heartworm antigen tests detect protein secreted mainly by adult female *Dirofilaria immitis* (Courtney and Cornell, 1990), and the most useful microfilaria tests concentrate microfilariae (modified Knott or filtration test) and allow for greater sensitivity (Georgi and Georgi, 1992; Knott, 1939). The earliest that heartworm antigen and microfilariae can be detected is about 5 and 6 months post infection, respectively. Antigenemia usually precedes but sometimes lags the appearance of microfilariae by a few weeks. Antigen may never be detected or may only be sporadically detected in dogs with very low female worm burdens (Atkins, 2003; McCall, 1992). In addition, antigenemia may be suppressed until about 9 months post infection in infected dogs receiving macrocyclic lactone preventive (McCall et al, 2001b). To determine when testing might become useful, a pre-detection period should be added to the approximate date on which infection may have been possible. A reasonable interval is 7 months. Thus, there is no need or justification for testing a dog for antigen and microfilariae prior to 7 months of age.

Microfilaria and Antigen Testing

Whether screening a population of asymptomatic dogs or seeking verification of a suspected heartworm infection, antigen testing is the most sensitive diagnostic method. It is now recommended, however, that microfilaria testing be done in tandem with antigen testing. This is especially important if there is a high degree of suspicion or if the heartworm prevention history is unknown (e.g., dogs adopted from shelters). It has come to light that in some dogs infected with heartworms, antigen blocking, presumably from antigen-antibody complexes, may lead to false-negative antigen test results. These dogs will be antigen negative and possibly microfilariae positive; a study conducted on shelter dogs in the southeastern United States reported this occurred at a rate of 7.1% (Velasquez et al, 2014). It is important that these dogs are identified and treated

to decrease the potential for selection of resistant subpopulations of heartworms. There will be instances where an infected dog is both antigen and microfilaria negative.

Antigen Tests

Enzyme-linked immunosorbent assay (ELISA) and immunochromatographic test systems are available for detecting circulating heartworm antigen. Each testing format has proven to be clinically useful. The current generation of heartworm antigen tests identifies most “occult” (adult worms present but no circulating microfilariae) infections consisting of at least one mature female worm and are nearly 100% specific (Atkins, 2003; Courtney and Zeng, 2001; Lee et al, 2011; McCall et al, 2001b). Differences in sensitivity exist especially in cases with low worm burdens and/or low antigenemia. Currently there are no verified tests capable of detecting infections consisting of only adult male worms.

To obtain reliable and reproducible results, antigen tests must be performed in strict compliance with the manufacturer’s instructions. Accuracy of all heartworm tests under field conditions is influenced by adherence to the instructions and storage and handling of the test kit and sample. This process has been simplified for several test kits that use devices that minimize the number of steps and partially automate the procedure. Both false-positive and false-negative results can occur. When a test result is unexpected, either positive or negative, the test should be repeated. If the result remains ambiguous, independent confirmation by a reference laboratory is recommended to confirm or refute the result.

While a positive heartworm antigen test indicates the presence of specific heartworm antigen, there are factors that can initiate a false-positive result. Currently, it is recommended that all positive antigen tests be confirmed through additional testing prior to the administration of any therapy including the use of macrocyclic lactones, doxycycline, or melarsomine. Confirmation is accomplished upon the identification of circulating microfilariae, or when a positive result is obtained utilizing a different manufacturer’s antigen test. Ultrasonographic visualization of adult heartworms within the heart or pulmonary artery is also confirmatory. Thoracic radiography depicting signs of heartworm disease, while not diagnostic of current infection, can be supportive of heartworm

disease. In general, it is better to trust rather than reject positive antigen test results.

The amount of antigen in circulation bears a direct, but imprecise, relationship to the number of mature female heartworms (Courtney, 1987). A graded test reaction can be recognized by ELISA test systems, but quantitative results are not displayed by immunochromatographic tests. The utility of the ELISA tests for assessing the degree of parasitism is limited by confounding complications such as the transient increase in antigenemia associated with recent worm death, low antigen levels from infections with young adult female worms and/or only a few adult females (Grieve and Knight, 1985; Wang, 1998), and the presence of antigen-antibody complexes which can reduce or completely block antigen detection. Therefore, quantitative analysis of antigen results is highly speculative and requires correlation with other relevant information. In as much, the color intensity of a positive antigen test result cannot reliably be used to determine the level of heartworm burden, and the use of antigen testing in this manner should be largely discouraged.

False-negative test results occur most commonly when infections are light, female worms are immature, only male worms are present, and/or the test kit instructions have not been followed. There are also suspected cases of antigen blocking from antigen-antibody complexes interfering with antigen testing, resulting in false-negative tests. Laboratory studies have shown that heating serum will release blocked antigen, and result in more positive test results (Velasquez et al, 2014). (For more on heat treatment, see the box on page 16).

A negative antigen test result does not verify an animal to be free of heartworm infection; it simply indicates that no antigen can be detected by that particular testing methodology. As such, a negative test result should be interpreted (and perhaps documented) more accurately as no antigen detected (NAD) rather than “negative.”

Microfilaria Tests

In areas where the prevalence of heartworm infection is high, many (~20%) heartworm-infected dogs may not be microfilaremic, and this figure is even higher for dogs on a macrocyclic lactone prevention program (McCall, 2005). Considering this, most microfilaremic dogs can be detected by microscopically examining a drop of fresh blood under a cover slip for microfilariae or cell

When Should Heat Treatment of Serum Samples Be Considered?

Heat treatment of serum samples prior to heartworm antigen tests as well as other non-heat methods to release blocked antigen is currently available through reference laboratories. This process should be considered when a negative antigen test result does not correlate with the presence of circulating microfilariae, or when there is suspicion of active clinical disease. However, the routine heating of blood samples IS NOT PRESENTLY RECOMMENDED for routine heartworm screening.

While heat treatment of samples has been shown to release blocked antigen that can cause false-negative test results, it is contrary to the label instructions for commonly used in-house tests and may interfere with the accuracy of results of not only heartworm testing but also the results of combination tests that include antibody detection of other infectious agents. Further studies on the possible cross-reactivity of heartworms with other helminths are needed to more accurately interpret the conversion from “no antigen detected” to “antigen positive” after heat treatment.

How to Perform the Modified Knott Test

The modified Knott test is performed by mixing 1.0 mL of EDTA blood with 9.0 mL of 2% formalin in a centrifuge tube. The tube is inverted several times to mix the blood with the formalin solution, lysing the red blood cells. The tube is then placed in a centrifuge, spun at 1100 to 1500 rpm for 5 to 8 minutes, and the liquid is poured off leaving the sediment. A drop of methylene blue is added to the sediment and then the stained sediment is placed on a glass slide and a cover slip applied. The slide is examined under low power (100X) for the presence of microfilariae. To observe the characteristics of the microfilariae, the slide can be examined under high-dry (400X). The microfilariae of *Dirofilaria immitis* are 295 to 325 microns (μm) long and have tapered heads. The microfilariae of *Acanthocheilonema reconditum* are 250 to 288 μm long with blunt heads and curved tails (**Figure 4**) (Rawlings, 1986).

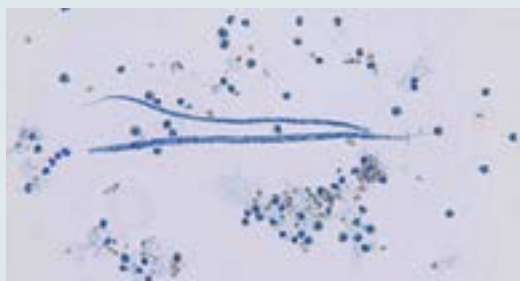


Figure 4. *Acanthocheilonema reconditum* (top) and *Dirofilaria immitis* (below). Photograph courtesy of Byron Blagburn, PhD.

movement caused by the motile microfilariae (Rawlings, 1986). A stationary rather than a migratory pattern of movement is indicative of a *Dirofilaria* species, nearly always *D. immitis* in the United States. Movement above the buffy coat in a microhematocrit tube also may be visible. These are insensitive testing methods when low numbers (50–100/mL) of microfilariae are present; however, such patients are at a lower risk for severe reaction after the administration of a microfilaricide and are less likely to pose a threat as a reservoir of infection.

For more accurate results a concentration technique (modified Knott test) should be used to determine the absence or presence of microfilariae (Georgi and Georgi, 1992; Knott, 1939). The modified Knott test (see box on left) remains the preferred method for observing morphology and measuring body dimensions to differentiate *D. immitis* from non-pathogenic filarial species, such as *Acanthocheilonema* (formerly *Dipetalonema*) *reconditum*.

All dogs should be tested for microfilariae. Microfilaremia validates serologic results, identifies the patient as a reservoir of infection, and alerts the veterinarian to a high microfilariae burden, which may precipitate a severe reaction following administration of a microfilaricide.

Testing Considerations Following Noncompliance and When Changing Products

In instances of noncompliance or changing the brand or type of heartworm preventive, it is important to determine the heartworm status of the

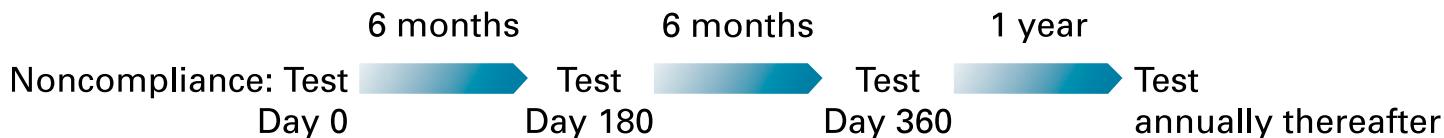

Figure 5. The testing protocol following known noncompliance includes three tests in the first year, with annual testing thereafter.

dog. The dog should be antigen and microfilaria tested prior to starting or changing products. A positive test indicates preexisting infection. The dog should always be retested 6 months later (**Figure 5**). A positive test at this time would most likely be due to an infection acquired before starting or resuming preventive therapy; however, in rare instances, an existing infection might be missed (i.e., false-negative test due mainly to young or low worm burden infection). Antigen and microfilaria testing should be performed on the one-year anniversary date of the initial test and annually thereafter.

Other Diagnostic Aids

Additional testing methods, such as radiography and echocardiography, are useful for confirming the diagnosis and staging the severity of heartworm disease.

Radiography

Assessment of cardiopulmonary status may be useful for evaluating a patient’s prognosis. Radiography provides the most objective method of assessing the severity of heartworm cardiopulmonary disease secondary to heartworm infection. Typical (nearly pathognomonic) signs of heartworm vascular disease are enlarged, tortuous, and often truncated peripheral intralobar and interlobar branches of the pulmonary arteries, particularly in the diaphragmatic (caudal) lobes (**Figure 6**). These findings are accompanied by variable degrees of pulmonary parenchymal disease. The earliest and most subtle pulmonary arterial changes are most commonly found in the dorsal caudal wedge of the diaphragmatic lung lobes. As the severity of infection and chronicity of disease progress, the pulmonary arterial signs are seen in successively larger branches (**Figure 7**). In the worst cases, the right heart eventually enlarges (Bowman and Atkins, 2009; Calvert and Rawlings, 1988; Rawlings, 1986).

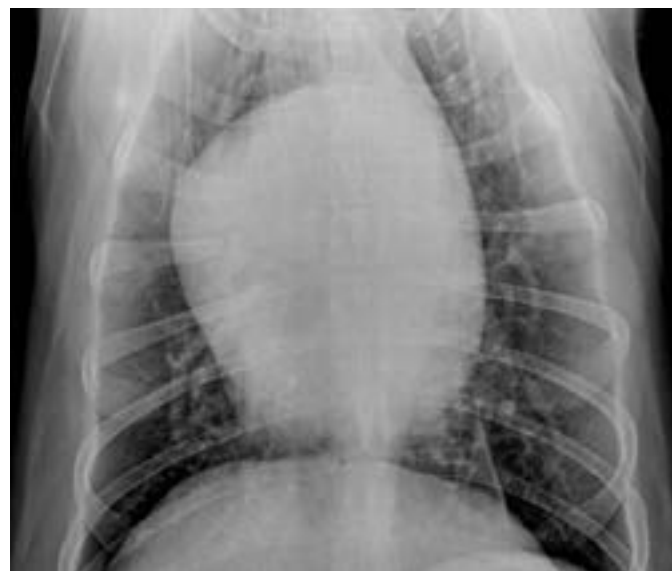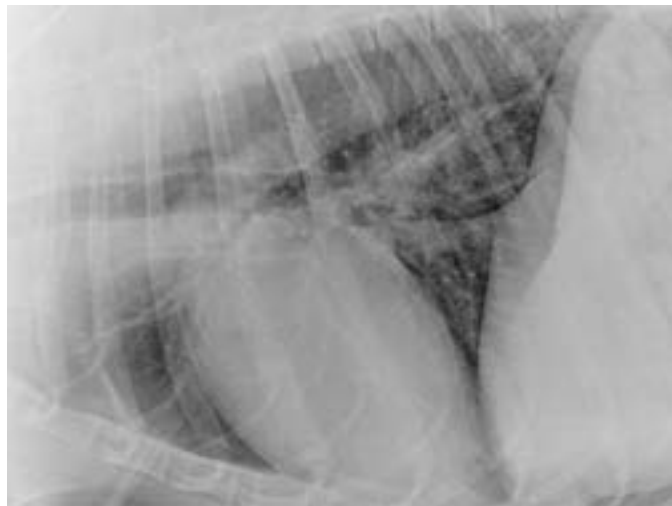


Figure 6. Moderate heartworm disease. Right heart enlargement (reverse “D” shape) is seen in heartworm disease. Radiographic images courtesy of C. Thomas Nelson, DVM.

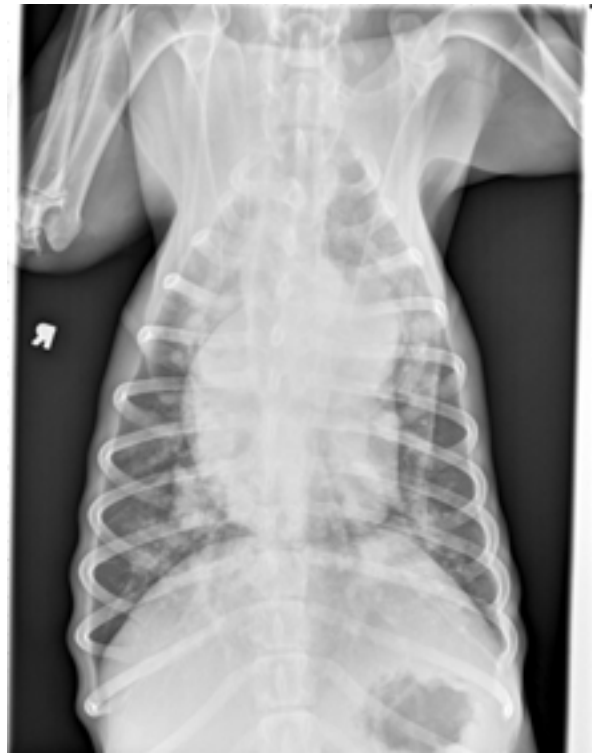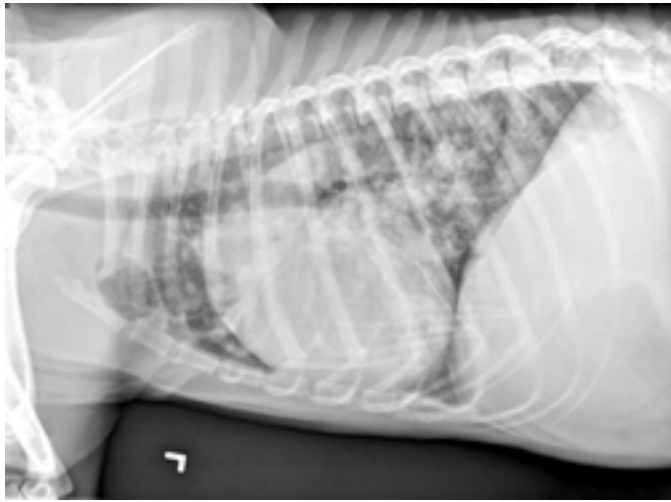


Figure 7. Severe heartworm disease. Dorsoventral and left lateral thoracic radiographs. There is severe right heart and main pulmonary artery enlargement and the peripheral pulmonary arteries are enlarged and tortuous. A diffuse, mixed bronchial and nodular-interstitial pattern is seen. The loss of abdominal serosal detail is due to ascites. These images show the combined heartworm disease sequelae of right heart failure, active pulmonary disease, pulmonary hypertension, and (likely) chronic and acute pulmonary arterial embolism. Radiographic images courtesy of Marisa Ames, DVM.

Echocardiography

The body wall of adult heartworms is highly echogenic and produces distinctive, short parallel-sided images with the appearance of “equal signs” where the imaging plane cuts across loops of the parasite. Echocardiography can provide definitive evidence of heartworm infection and also allows for assessment of cardiac anatomic and functional consequences of the disease (**Figure 8**). It is not an efficient method of making this diagnosis, however, particularly in lightly infected dogs, because the worms often are limited to the peripheral branches of the pulmonary arteries beyond the echocardiographic field of view. When heartworms are numerous, they are more likely to be present in the main pulmonary artery, right and proximal left interlobar branches or within the right side of the heart where they can be imaged easily. In dogs with hemoglobinuria, visualization of heartworms in the orifice of the tricuspid valve provides conclusive confirmation of caval syndrome (Badertscher et al, 1988; Moise, 1988; Venco et al, 2001).

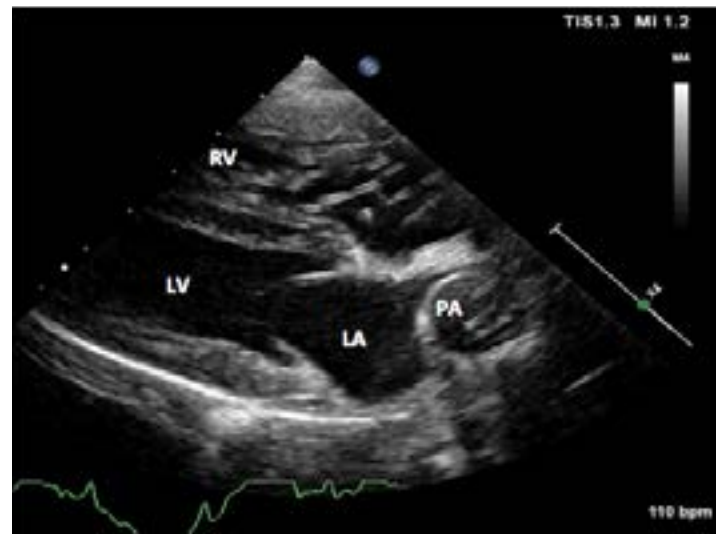

Figure 8. Right parasternal long axis echocardiographic view from an 8-year-old castrated male mixed breed dog that presented for lethargy. There is a large mass of heartworms crossing the tricuspid valve. The right ventricle is severely hypertrophied and the right atrium is dilated. Worms can also be seen within the severely dilated pulmonary artery. LA, left atrium; LV, left ventricle; PA, pulmonary artery; RV, right ventricle. Image courtesy of Dr. Marisa Ames.

Diagnostics for Pre-Adulticide Evaluation in an Infected Dog

The extent of diagnostic testing necessary in the pre-adulticide evaluation varies depending on the clinical status of each patient. Selected clinical and laboratory tests should only be performed to complement information obtained from a thorough history, physical examination, and antigen and microfilaria tests. It is important to note that some key factors influencing the probability of post-adulticide thromboembolic complication and outcome of treatment are not easily measured with standard diagnostic procedures, including 1) the activity level of the dog, 2) the extent of concurrent pulmonary vascular disease, and 3) the severity of infection (high versus low worm burdens).

Adult heartworms are a grave risk to our canine patients. The longer they remain in an animal, the greater the damage to the cardiopulmonary system and the greater the risk of illness and death.

Restricting activity is imperative as exercise, excitement, and overheating are harbingers of complications. High activity level of the dog during treatment and for 6 to 8 weeks after the last melarsomine injection is one of the most significant factors contributing to post-adulticidal complications (Dillon et al, 1995; Fukami et al, 1998). Prior to treatment, the owner's ability and willingness to properly confine treated dogs should be thoroughly investigated. A helpful resource for pet owners, "[Battling Boredom: Tips for Surviving Cage Rest](#)," is available on the American Heartworm Society website.

Thoracic radiographs can assist in providing an assessment of the animal's cardiopulmonary status and can be helpful in evaluating the potential for post-adulticide treatment complications

(Calvert and Rawlings, 1988; Rawlings, 1986). Thromboembolic disease is commonly seen in infected dogs exhibiting radiographic signs of severe pulmonary arterial obstruction, especially in those animals presenting with clinical signs (Rawlings et al, 1993b). Regardless of radiographic findings, heartworms must be eliminated, although not necessarily immediately, in all patients that can tolerate the death of worms.

The greater the number of heartworms killed during an adulticide treatment, the more significant the potential for obstructive and inflammatory pathology (Venco et al, 2004). Unfortunately, no test (or combination of tests) is available to accurately determine the number of heartworms present. Whether carrying low or high worm burdens, infected dogs can be clinically asymptomatic and have minimal radiographic changes. So, even with extensive diagnostics, predicting post-adulticide complications is difficult. One must always assume post-treatment complications are likely, and every infected pet must be managed as though a substantial heartworm mass is present or a potentially violent individual immune reaction to the dead and dying worms could occur.

Historically, due to financial limitations of some pet owners and animal shelters, large numbers of adulticide treatments have been successfully performed without the benefit of extensive diagnostics. While diagnostics can be an important part of defining an individual's heartworm disease status, each plan must be developed considering both the animal and individual pet owner. No set protocol has been established for pre-treatment workup and reasonable judgment should always be used to weigh the necessity, benefit, and extent of each diagnostic procedure performed.

Adult heartworms are a grave risk to our canine patients. The longer they remain in an animal, the greater the damage to the cardiopulmonary system and the greater the risk of illness and death. It is probable that treating in the absence of diagnostics, while not ideal, is better than refusing to perform a needed treatment.

KEY POINTS: HEARTWORM TREATMENT

- The goals of any heartworm treatment are to improve the clinical condition of the animal and to eliminate all life stages of the heartworms (microfilariae, larval stages, juveniles, and adults) with minimal post-treatment complications.
- Dogs exhibiting significant clinical signs of heartworm disease should be stabilized before administering an adulticide; this may require administration of glucocorticosteroids, diuretics, vasodilators, positive inotropic agents, and fluid therapy.
- Melarsomine, administered via deep intramuscular injection into the belly of the epaxial lumbar muscles (between L3 and L5), is the only adulticidal drug approved by the FDA.
- Exercise restriction during the entire treatment and recovery period is ESSENTIAL for minimizing cardiopulmonary complications, as there is a distinct correlation between the activity level of the dog and the severity of disease.
- Adjunct therapy with doxycycline for 4 weeks prior to the administration of melarsomine eliminates *Wolbachia*, an endosymbiont bacteria harbored within *D. immitis*, reduces pathology associated with dead heartworms, and disrupts heartworm transmission.
- A macrocyclic lactone preventive should be administered for 2 months prior to administering melarsomine to reduce new infections and eliminate existing susceptible larvae.
- The effectiveness of the macrocyclic lactone can also be potentiated with concurrent use of doxycycline for 4 weeks, as this will essentially eliminate all developing larvae during the first 60 days of treatment.
- Caval syndrome, which develops acutely in some heavily infected dogs when adult heartworms partially obstruct blood flow through the tricuspid valve, usually ends fatally within 2 days if surgical extraction of the worms is not pursued promptly.

PRINCIPLES OF HEARTWORM TREATMENT

Treating heartworm infections in asymptomatic patients or those exhibiting signs of mild disease usually is not problematic if exercise is curtailed. Infections associated with moderate or severe heartworm disease (**Table 1**) or in patients with concurrent disease often are challenging.

The goals of any heartworm treatment are to improve the clinical condition of the animal and to eliminate all life stages of the heartworms (microfilariae, larval stages, juveniles, and adults) with minimal post-treatment complications. Dogs exhibiting significant clinical signs of heartworm disease should be stabilized before administering an adulticide. This may require administration of glucocorticosteroids, diuretics, vasodilators, positive inotropic agents, and fluid therapy.

A thorough understanding of the host–parasite relationship is necessary to effectively manage all cases. As expected, the number of worms has an effect on the severity of disease; but of equal, if not greater, importance is the activity level of the dog. Controlled studies have shown that dogs infected by surgical transplantation with 50 heartworms and exercise-restricted took longer to develop clinical disease and developed less pulmonary vascular disease than dogs with 14 heartworms and allowed moderate activity (Dillon et al, 1995). This was also evident in a study in naturally infected dogs where there was no correlation between the number of heartworms and pulmonary vascular resistance and is an indication that the host–parasite interaction plays a significant role in the severity of disease (Calvert, 1986). A subsequent study reported similar findings in dogs being treated with melarsomine (Fukami et al, 1998).

Whereas live heartworms can cause endarteritis and muscular hypertrophy of arteriolar walls, primarily of the caudal pulmonary arteries, dying and dead heartworms cause a significant portion of pathology

- The American Heartworm Society's recommended heartworm management protocol is outlined in detail in Table 2 (see page 25).

Table 1. Summary of Clinical Signs of Canine Heartworm Disease

Mild	Asymptomatic or cough
Moderate	Cough, exercise intolerance, abnormal lung sounds
Severe	Cough, exercise intolerance, dyspnea, abnormal heart and lung sounds, enlarged liver (hepatomegaly), syncope (temporary loss of consciousness from reduced blood flow to the brain), ascites (fluid accumulation in the abdominal cavity), death
Caval Syndrome	Sudden onset of severe lethargy and weakness accompanied by hemoglobinemia and hemoglobinuria

seen in clinical disease (**Figures 9 and 10**). As worms die from either natural causes or as a result of adulticidal therapy, they collapse and are forced by the blood flow into the distal branches of the pulmonary arteries. These dead worms, along with the elicited inflammation and platelet aggregation, result in thromboembolic disease. During periods of increased activity or exercise, the increased blood flow to these blocked vessels can cause capillary delamination, rupture, and subsequent fibrosis (Case et al, 1995; Dillon et al, 1995; Hoskins et al, 1985; Rawlings et al, 1993a). As blood flow becomes restricted, pulmonary artery pressures can increase, and in severe cases, right-sided heart failure can ensue. There is a distinct correlation between the activity level of the dog and the severity of disease.

Adulticide Therapy

Melarsomine Dihydrochloride

Melarsomine, administered via deep intramuscular injection into the belly of the epaxial lumbar muscles (between L3 and L5), is the only adulticidal drug approved by the FDA. Mild swelling and some

soreness at the injection site may be present for a few days, but this can be minimized by ensuring that the injection is deposited into the belly of the epaxial musculature with a needle newly changed after the drug is drawn into the syringe and of appropriate length and gauge for the size of dog and body condition. Strictly adhering to the manufacturer's instructions for administration is imperative. Administration of an analgesic such as tramadol or hydrocodone at the time of injection reduces the acute myalgia associated with melarsomine. Exercise restriction during the recovery period is ESSENTIAL for minimizing cardiopulmonary complications (see Pulmonary Thromboembolism).

Melarsomine has been shown to have activity against immature worms 2 and 4 months old (Dzimianski et al, 1990; Dzimianski et al, 1989, McCall et al, 2010); however, activity against 3, 5, and 7 month old worms has not been assessed. The two-injection protocol with melarsomine (i.e., two injections of 2.5 mg/kg body weight 24 hours apart)

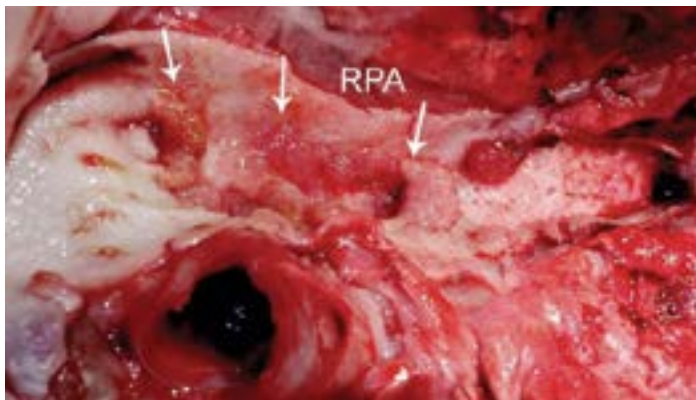


Figure 9. Image of the main trunk of the right pulmonary artery (RPA) exhibiting significant endothelial proliferation (white arrows). Photograph courtesy of Stephen Jones, DVM.

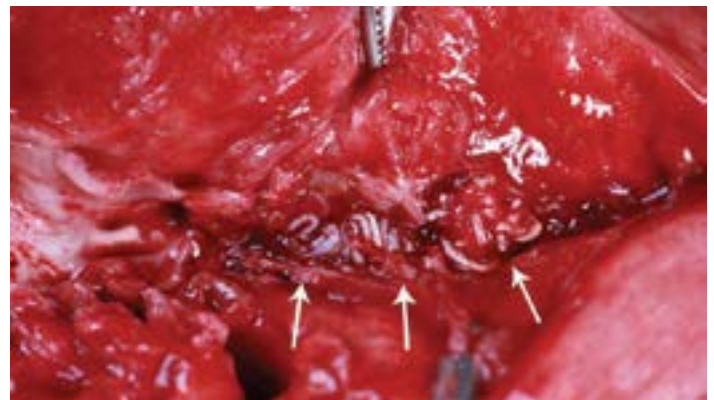


Figure 10. Image of a dead adult heartworm (white arrows) lodged in a distal pulmonary artery. Photograph courtesy of Stephen Jones, DVM.

listed on the product insert for treating class 1 and 2 heartworm disease kills only about 90% of the adult worms. The three-dose alternate protocol (one injection of 2.5 mg/kg body weight followed at least one month later by two injections of the same dose 24 hours apart) listed for treating class 3 heartworm disease kills 98% of the worms (Keister et al, 1992; Vezzoni et al, 1992). These overall efficacy values reflect the percentage of worms killed in groups of dogs and not the percentage of dogs cleared of worms, which are considerably lower than these overall efficacy values. The three-dose protocol has the added advantage of decreased complication rates and increased safety as a number of the adult worms are killed with the first melarsomine injection and most, if not all, of the remaining worms are killed with the second and third injections.

Staging of the disease, as described on the melarsomine label, and use of the two-dose protocol has failed to adequately ensure treatment success. Therefore, regardless of the severity of the disease (with the exception of caval syndrome), the three-dose protocol is recommended by the American Heartworm Society due to the increased safety and efficacy.

Pulmonary Thromboembolism

Pulmonary thromboembolism is an inevitable consequence of successful adulticide therapy and may be severe if infection is heavy and pulmonary arterial disease is extensive. If signs of embolism (low grade fever, cough, hemoptysis, exacerbation of right heart failure) develop, they are usually evident within 7 to 10 days, but occasionally as late as 4 weeks after completion of adulticide administration (Hirano et al, 1992). Mild embolism in relatively healthy areas of lung may be clinically unapparent. A pivotal factor in reducing the risk of thromboembolic complications is STRICT exercise restriction.

Adjunct Therapy

Steroids

Administration of diminishing anti-inflammatory doses of glucocorticosteroids helps control clinical signs of pulmonary thromboembolism (Atwell and Tarish, 1995). Whereas studies showed a decrease in efficacy of the arsenical thiacetarsamide when glucocorticosteroids were administered concurrently (Rawlings et al, 1984), a study showed no decrease in the efficacy of melarsomine when

Staging of the disease, as described on the melarsomine label, and use of the two-dose protocol has failed to adequately ensure treatment success. Therefore, regardless of the severity of the disease (with the exception of caval syndrome), the three-dose protocol is recommended by the American Heartworm Society due to the increased safety and efficacy.

used in conjunction with prednisone (Dzimianski et al, 2010); therefore, the use of glucocorticoids is recommended.

NSAIDs/Aspirin

The empirical use of aspirin for its antithrombotic effect or to reduce pulmonary arteritis is not recommended for heartworm-infected dogs (Boudreaux et al, 1991). Convincing evidence of clinical benefit is lacking and there is some research suggesting that aspirin may be contraindicated.

Doxycycline

Many filarial nematodes, including *Dirofilaria immitis*, harbor obligate, intracellular, gram-negative, endo-symbiotic bacteria belonging to the genus *Wolbachia* (Rickettsiales) (Kozek, 2005; Taylor et al, 2005). Doxycycline reduces *Wolbachia* numbers in all stages of heartworms. Doxycycline administration during the first or second month following experimental heartworm infection was lethal to third- and fourth-stage heartworm larvae (McCall et al, 2011). In addition, in dogs with adult infections, doxycycline gradually suppressed microfilaremia (Bazzocchi et al, 2008; McCall et al, 2008a). Microfilariae ingested by mosquitoes on dogs treated with doxycycline developed into third-stage larvae that appeared to be normal in appearance and motility, but these larvae were not able to develop into adult worms, thus reducing the risk of selecting for resistant subpopulations (McCall et al, 2008a, 2014a).

Wolbachia have also been implicated as a component in the pathogenesis of filarial diseases, possibly through their metabolites (Bouchery et al, 2013; Kramer et al, 2005). Recent studies have shown that a major *Wolbachia* surface protein (WSP) induces a specific IgG response in hosts infected by *D. immitis* (Kramer et al, 2005). It is hypothesized that *Wolbachia* may contribute to pulmonary and renal inflammation through its WSP.

When incorporated into a heartworm treatment protocol, doxycycline should be given before administration of melarsomine so the *Wolbachia* organisms and their metabolites are reduced or absent when the worms die. Doxycycline is administered at 10 mg/kg BID for 4 weeks (Bandi et al, 1999; Kramer et al, 2011; Nelson et al, 2017). Protocols using a lesser dose or shorter duration have not been established. A one-month wait period after administration of doxycycline but before administration of melarsomine is currently recommended as it is hypothesized to allow time for the WSPs and other metabolites to decrease before killing the adult worms. It also potentially allows more time for the worms to wither as they become unthrifty after the *Wolbachia* endosymbionts are eliminated.

Doxycycline has been shown to eliminate over 95% of the *Wolbachia* organisms in the filarial nematode *Wuchereria bancrofti*, resulting in amicrofilaremia for 12 months (Hoerauf et al, 2003). These data suggest that the presence of *Wolbachia*, or at least very low numbers of the organism, is necessary for embryogenesis. In *D. immitis* (adults and microfilariae) data suggest *Wolbachia* numbers remain low for at least 12 months following doxycycline administration (Rossi et al, 2010).

Minocycline has been shown to be highly effective in eliminating *Wolbachia* organisms from the filarial nematode *Onchocerca gutturosa* (Townson et al, 2006). No published studies have been conducted in *D. immitis* but available pharmacological data and anecdotal reports suggest this is a viable alternative if doxycycline is not available. The dosing regimen is the same as doxycycline.

The use of doxycycline tablets/capsules or minocycline for oral administration to a dog is considered Extra Label Drug Use and is permitted under the Animal Medicinal Drug Use Clarification Act of 1994 (AMDUCA).

Macrocylic Lactones

It is highly probable that a heartworm-positive dog harbors heartworms that can range from less than 1 month to as much as 7 years of age. The potential incomplete efficacy of melarsomine against young adult worms could present a problem in achieving the goal of eliminating all of the worms.

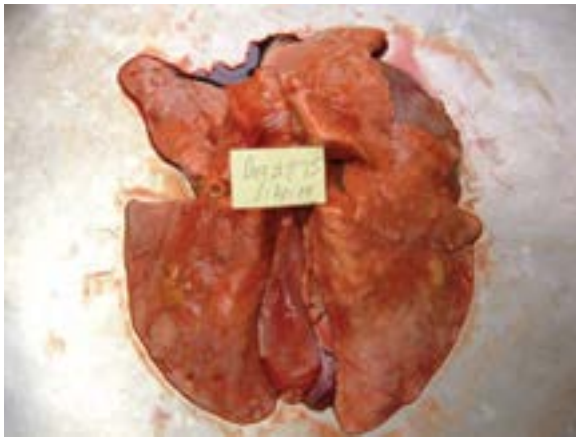
A macrocylic lactone preventive should be administered for 2 months prior to administering melarsomine to reduce new infections and eliminate existing susceptible larvae. The effectiveness of the macrocylic lactone can also be potentiated with concurrent use of doxycycline for 4 weeks, as this will essentially eliminate all developing larvae during the first 60 days of treatment.

Macrocylic lactones administered as microfilaricides may cause a rapid decrease in the numbers of microfilariae and should be used with caution in dogs with high microfilarial counts. Pretreatment with antihistamines and glucocorticosteroids will minimize potential reactions. Topical moxidectin is now FDA-approved for use in heartworm-positive dogs to eliminate microfilariae. No adverse reactions due to high microfilarial counts were observed in the laboratory or field studies conducted for approval of this label claim (McCall et al, 2014b).

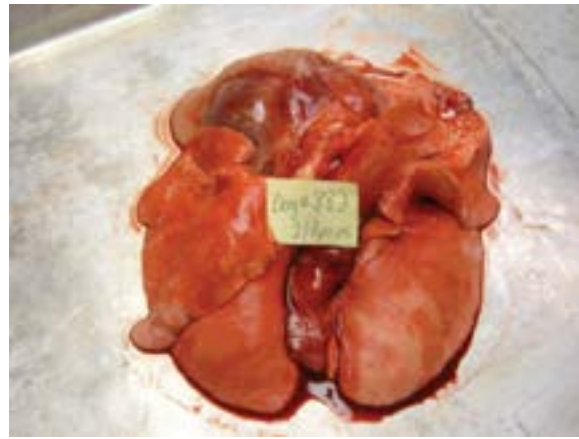Macrocylic Lactones/Doxycycline

Studies have shown that experimentally infected heartworm-positive dogs pretreated with ivermectin and doxycycline prior to receiving melarsomine injections had less pulmonary pathology associated with the death of the heartworms (**Figure 11**) (Kramer et al, 2011; McCall et al, 2008a).

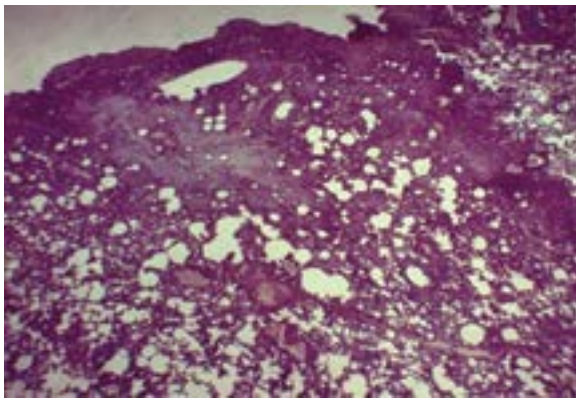
Select macrocylic lactones (ivermectin and moxidectin) coupled with doxycycline individually suppress embryogenesis, weaken adult heartworms, and have adulticidal activity (McCall et al, 2008a; Grandi et al, 2010; Savadelis et al, 2017; Ames et al, 2017). As mentioned previously doxycycline reduces *Wolbachia* levels in all stages of heartworms. Studies have shown that administration of doxycycline in combination with ivermectin provided more rapid adulticidal activity than ivermectin alone as well as reducing *Wolbachia* numbers more effectively than doxycycline alone (Bazzocchi et al, 2008). No studies have been published on combining milbemycin or selamectin with doxycycline.



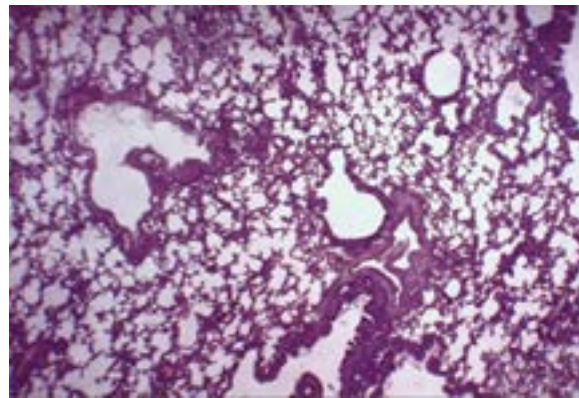
Melarsomine only



Ivermectin / Doxycycline / Melarsomine



Melarsomine only



Ivermectin / Doxycycline / Melarsomine

Figure 11. Pulmonary pathology associated with the death of heartworms in experimentally infected heartworm-positive dogs pretreated with ivermectin and doxycycline prior to receiving melarsomine injections. Photographs courtesy of John McCall, PhD and Laura Kramer, DVM, PhD.

In cases where arsenical therapy is not possible or is contraindicated, the use of a monthly oral ivermectin or topical moxidectin heartworm preventive along with doxycycline at 10 mg/kg BID for a 4-week period might be considered. It should be noted that this protocol is **NOT RECOMMENDED** as a standard first-line treatment but instead as a salvage procedure. The safety and long-term effects of these protocols have not been evaluated. In one study in client-owned animals in which exercise restriction was not enforced (Ames et al, 2017), coughing during the treatment period was twice (44%) the reported rate of treatment with melarsomine alone and six times the rate reported in the AHS recommended treatment protocol described below (see **Table 2**). In another study of experimentally infected dogs treated with doxycycline and topical moxidectin, radiographic evidence of disease progressed at the same rate as untreated controls and arterial thrombi scores were significantly higher in the treated dogs (Savadelis et al, 2017). In comparison, dogs treated with

ivermectin, doxycycline, and melarsomine had a virtual absence of thrombi (Kramer et al, 2011).

An antigen test should be performed every 6 months and the dog should not be considered cleared until two consecutive NAD (no antigen detected) heartworm antigen tests, 6 months apart, have been obtained. If the dog is still antigen positive after one year, repeat the doxycycline therapy. Exercise should be rigidly restricted for the duration of the treatment process.

AHS-Recommended Treatment Protocol

The AHS recommends a multimodal approach to treating heartworms based on the information presented above and depicted in the following example management protocol (**Table 2**) (Nelson, 2012).

A retrospective study of clinical cases comparing the protocol listed in Table 2 with a similar protocol without doxycycline showed a decrease

Table 2. AHS-Recommended Heartworm Management Protocol

Day	Treatment
Day 0	<p>In a dog diagnosed and verified as heartworm positive:</p> <ul style="list-style-type: none"> • Positive antigen (Ag) test verified with microfilaria (MF) test • If no MF are detected, confirm with second Ag test from a different manufacturer • Apply an EPA-registered canine topical product labeled to repel and kill mosquitoes • Begin exercise restriction—the more pronounced the signs, the stricter the exercise restriction <p>If the dog is symptomatic:</p> <ul style="list-style-type: none"> • Stabilize with appropriate therapy and nursing care • Prednisone prescribed at 0.5 mg/kg BID first week, 0.5 mg/kg SID second week, 0.5 mg/kg every other day (EOD) for the third and fourth weeks
Day 1	<ul style="list-style-type: none"> • Administer appropriate heartworm preventive <ul style="list-style-type: none"> ◦ If MF are detected, pre-treat with antihistamine and glucocorticosteroids, if not already on prednisone, to reduce risk of anaphylaxis ◦ Observe for at least 8 hours for signs of reaction
Days 1–28	<ul style="list-style-type: none"> • Administer doxycycline 10 mg/kg BID for 4 weeks <ul style="list-style-type: none"> ◦ Reduces pathology associated with dead heartworms ◦ Disrupts heartworm transmission
Day 30	<ul style="list-style-type: none"> • Administer appropriate heartworm preventive • Apply an EPA-registered canine topical product to repel and kill mosquitoes
Days 31-60	<p>A one-month wait period following doxycycline before administering melarsomine is currently recommended as it is hypothesized to allow time for the <i>Wolbachia</i> surface proteins and other metabolites to dissipate before killing the adult worms. It also allows more time for the worms to wither as they become unthrifty after the <i>Wolbachia</i> endosymbionts are eliminated.</p>
Day 61	<ul style="list-style-type: none"> • Administer appropriate heartworm preventive • Administer first melarsomine injection, 2.5 mg/kg intramuscularly (IM) • Prescribe prednisone 0.5 mg/kg BID first week, 0.5 mg/kg SID second week, 0.5 mg/kg EOD for the third and fourth weeks • Decrease activity level even further: cage restriction; on leash when using yard
Day 90	<ul style="list-style-type: none"> • Administer appropriate heartworm preventive • Administer second melarsomine injection, 2.5 mg/kg IM • Prescribe prednisone, 0.5 mg/kg BID first week, 0.5 mg/kg SID second week, 0.5 mg/kg EOD for the third and fourth weeks
Day 91	<ul style="list-style-type: none"> • Administer third melarsomine injection, 2.5 mg/kg IM • Continue exercise restriction for 6 to 8 weeks following last melarsomine injections
Day 120	<ul style="list-style-type: none"> • Test for presence of MF <ul style="list-style-type: none"> ◦ If positive treat with a microfilaricide and retest in 4 weeks • Continue a year-round heartworm prevention program based on risk assessment described in prevention section
Day 365	<ul style="list-style-type: none"> • Antigen test 9 months after last melarsomine injection; screen for MF • If still Ag positive, re-treat with doxycycline followed by two doses of melarsomine 24 hours apart

in respiratory complications and mortality rates when doxycycline was included (Nelson et al, 2017). A study on experimentally infected dogs showed that dogs that received doxycycline and ivermectin prior to melarsomine administration had less severe arterial lesions and the virtual absence of thrombi (Kramer et al, 2011).

Elimination of Microfilariae

Macrocytic lactones administered as microfilaricides may cause a rapid decrease in the numbers of microfilariae and should be used with caution in dogs with high microfilarial counts. Pretreatment with antihistamines and glucocorticosteroids is advisable in the face of high microfilaria burdens to minimize potential reactions and the dog should be observed for the day after administration of a microfilaricide (Bowman and Atkins, 2009). Topical moxidectin is approved by the FDA to eliminate microfilariae (McCall et al, 2014a). No adverse reactions due to high microfilaria counts were observed in the laboratory or field studies conducted for approval of this label claim.

Pretreatment with antihistamines and glucocorticosteroids is advisable in the face of high microfilaria burdens to minimize potential reactions and the dog should be observed for the day after administration of a microfilaricide.

Historically, microfilaricidal treatment was usually done about 3 weeks to a month after adulticidal therapy, with the understanding that several weekly treatments were often required to completely eliminate circulating microfilariae (Knight, 1995; McCall et al, 2008b). Current protocols utilizing doxycycline in combination with regular preventive doses of macrocytic lactones have essentially eliminated the need for post-adulticidal elimination of microfilariae (Bazzocchi et al, 2008; McCall et al, 2008a) although microfilaria testing is still recommended. Administration of a macrocytic lactone should always begin as soon as the dog is diagnosed with a heartworm infection. Including

doxycycline in the treatment protocol as previously described hastens the elimination of microfilariae.

When elimination of microfilariae is accomplished in the course of heartworm treatment, a microfilaria test should be performed in adulticide-treated dogs at the time the antigen test is conducted 9 months post treatment. Controlling the spread of heartworms entails decreasing the microfilaremic reservoirs of infection in the dog population and the benefits of doing so have been cited (see HEARTWORM PREVENTION).

Surgical Extraction of Adult Heartworms

Caval Syndrome (Dirofilarial Hemoglobinuria)

Caval syndrome develops acutely in some heavily infected dogs when adult heartworms partially obstruct blood flow through the tricuspid valve and also interfere with valve closure (**Figure 12**). Severe passive congestion of the liver, a coarse systolic murmur of tricuspid regurgitation, and jugular pulsations are characteristic features of the syndrome. The diagnosis is based on a sudden onset of severe lethargy, dyspnea, pale mucous membranes, and weakness accompanied by hemoglobinemia and hemoglobinuria (Atwell and Buoro, 1988; Kitagawa et al, 1986; Venco, 1993). Caval syndrome can be confirmed conclusively by echocardiographic visualization of heartworms within the tricuspid orifice and posterior vena cava (**Figure 13**) (Atkins et al, 1988). The clinical course usually ends fatally within 2 days if surgical extraction of the worms is not pursued promptly.

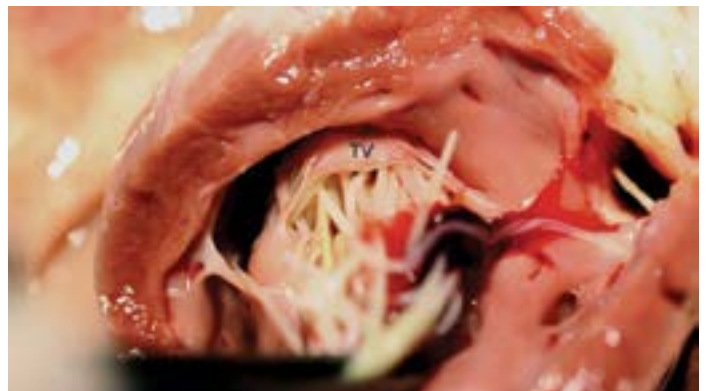

Figure 12. Image of a heart from a dog suffering from caval syndrome as viewed from the right ventricle toward the tricuspid valve (TV). A mass of heartworms completely occludes the valve preventing it from closing. Photograph courtesy of Stephen Jones, DVM.

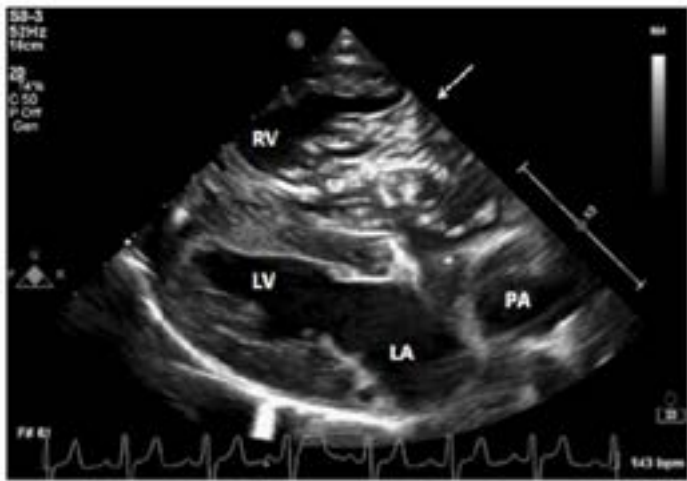

Figure 13. Right parasternal long-axis echocardiogram. There is a large mass of heartworms crossing the tricuspid valve (arrow). The right ventricle is hypertrophied and severely dilated. The right atrium and pulmonary artery are also dilated. LA, left atrium; LV, left ventricle; PA, pulmonary artery; RV, right ventricle. Image courtesy of Lauren Markovic, DVM.

Surgical removal of worms from the right atrium and orifice of the tricuspid valve can be accomplished using light sedation (may not be necessary), local anesthesia, and either a rigid or flexible alligator forceps or an intravascular retrieval snare introduced preferentially via the right external jugular vein (Yoon et al, 2013). With fluoroscopic guidance if available, the instrument should continue to be passed until worms can no longer be retrieved (**Figure 14**) (Ishihara et al, 1988; Jackson et al, 1977). Immediately following a successful operation, the murmur should soften or disappear and within 12 to 24 hours hemoglobinuria should disappear. Fluid therapy may be necessary in critically ill, hypovolemic dogs to restore hemodynamic and renal function. Within a few weeks following recovery from surgery, adulticide chemotherapy is recommended to eliminate any remaining worms, particularly if many are still visible echocardiographically.

Pulmonary Arterial Infections

The main pulmonary artery and lobar branches can be accessed with flexible alligator forceps aided by fluoroscopic guidance. Intraoperative mortality with this technique is very low. Overall survival and rate of recovery of dogs at high risk of pulmonary thromboembolism is improved significantly by physically removing as many worms as possible before beginning adulticide therapy (Morini et al, 1998). When the facilities are available, worm

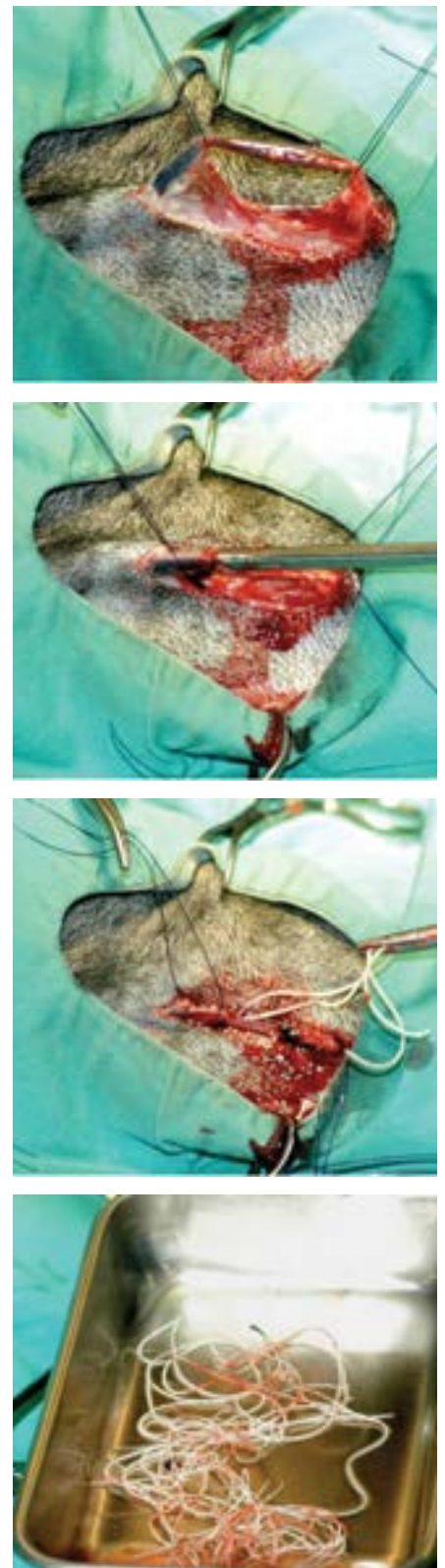


Figure 14. Surgical removal of worms. Photographs courtesy of C. Thomas Nelson, DVM.

extraction is the procedure of choice for the most heavily infected and high-risk dogs. Before electing this method of treatment, however, echocardiographic visualization of the right heart and pulmonary arteries should be performed to determine that a sufficient number of worms are in accessible locations.

Alternative Therapies

Long-term Macrocytic Lactone Administration

Any methods using continuous monthly administration of prophylactic doses of any macrocytic lactone alone are NOT RECOMMENDED. While effective in reducing the life span of juvenile and adult heartworms, the data suggest that the older worms are less susceptible, taking longer to die. The adulticidal effect of macrocytic lactones has been shown to take more than 2 years of continuous administration before adult heartworms are 95% eliminated, and the timing for rigid exercise restriction is unknown with this approach (McCall et al, 2001). Throughout this period, the infection would persist and pathology would continue to progress (Rawlings et al, 2001). Another important concern in using macrocytic lactones in monotherapy of heartworm-positive dogs as stand-alone therapy is the potential for selection of resistant subpopulations of heartworms (Bowman, 2012; Geary et al, 2011).

Herbal Therapies

No “natural” or herbal therapies have been shown to be safe and effective prevention or treatment for heartworm disease.

Compounded Medications

The use of compounded medications in the prevention and treatment of heartworm disease is seldom justified, not recommended, and in most circumstances, violates the Animal Medicinal Drug Use Clarification Act (AMDUCA). In addition to the legal ramifications there are concerns with stability and potency with compounded doxycycline (Papich et al, 2013) and macrocytic lactones and toxicity with compounded arsenicals.

Confirmation of Adulticide Efficacy

Clinical improvement is possible without completely eliminating the adult heartworms. Worms that do survive adulticide treatment are invariably the antigen-producing females (Kiestler et al, 1992). Most microfilaremic dogs with post-adulticide,

female unisex infections become occult within 6 to 9 months, with or without microfilaricide treatment, and particularly if they were treated with doxycycline and are on a macrocytic lactone preventive during and after adulticidal therapy (Grandi et al, 2010; McTier et al, 1994). Consequently, clinical improvement and successful clearance of microfilariae from the blood do not verify a complete adulticide effect. Recurrence of microfilaremia 6 months later may be due to incomplete clearance of adult worms, maturation of immature worms if a preventive and doxycycline was not given during adulticide therapy, or a new infection due to a lapse in preventive.

Heartworm antigen testing is the most reliable method of confirming the efficacy of adulticidal therapy. If all of the adult female worms have been killed, heartworm antigen should become undetectable by 6 months post treatment (Maxwell et al, 2014; McTier et al, 1994). However, this single test result does not verify that the dog is negative for heartworms, as larval and/or juvenile heartworms may be present in the dog and an insufficient amount of antigen is being produced by these young worms to elicit a positive test result. This is especially critical if a macrocytic lactone and doxycycline were not administered prior to or initiated concurrently with adulticidal therapy. If a heartworm-positive dog is immediately treated with adulticide and a macrocytic lactone is not given until 3 to 4 weeks after the last dose of adulticide, the dog should have a negative antigen test 7 months after the initial dose of macrocytic lactone before being considered cleared of adult worms. Because adult worms may continue to die for more than a month following adulticide administration, dogs that are still antigenemic at any time less than 9 months post treatment should be allowed more time to clear antigen before retreatment is considered.

Heartworm antigen testing is the most reliable method of confirming the efficacy of adulticidal therapy.

Elective Surgeries on Dogs with Heartworms

Veterinarians are frequently faced with the decision whether to perform an elective procedure, such as a spay or neuter, on a heartworm-positive dog. A study has shown no increase in perioperative complications in heartworm-positive dogs with no to mild clinical signs of heartworm disease (Peterson et al, 2014). Elective surgical procedures should be avoided in dogs exhibiting signs of more advanced disease, and treatment utilizing the protocol in Table 2 should be initiated. Surgery can then be performed 6 months after adulticidal treatment if the dog has recovered sufficiently.

REFERENCES

- Ames M. Use of moxidectin/imidacloprid and doxycycline for non-arsenical heartworm adulticidal therapy. Presented at ACVIM 2017 Forum, 2017.
- Atkins CE. Comparison of results of three commercial heartworm antigen test kits in dogs with low heartworm burdens. *J Am Vet Med Assoc.* 2003; 222:1221-1223.
- Atkins CE, Keene BW, McGuirk SM. Pathophysiologic mechanism of cardiac dysfunction in experimentally induced heartworm caval syndrome in dogs: an echocardiographic study. *Am J Vet Res.* 1988; 49:403-410.
- Atkins CE, Murray MJ, Olavessen LJ, et al. Heartworm 'lack of effectiveness' claims in the Mississippi Delta: Computerized analysis of owner compliance – 2004–2011. *Vet Parasitol.* 2014;206:106–113.
- Atwell RB, Buoro IBJ. Caval syndrome. In Boreman PFL, Atwell RB (eds): *Dirofilaria immitis*. Boca Raton, FL: CRC Press, 1988, pp 191-203.
- Atwell RB, Tarish JH. The effect of oral, low-dose prednisolone on the extent of pulmonary pathology associated with dead *Dirofilaria immitis* in a canine lung model. In *Proceedings of the Heartworm Symposium '95*, Auburn, AL. American Heartworm Society, 1995, pp 103-111.
- Badertscher RR, Losonsky JM, Paul AJ, Kneller SK. Two-dimensional echocardiography for diagnosis of dirofilariasis in nine dogs. *J Am Vet Med Assoc.* 1988;193:843-846.
- Bandi C, McCall JW, Genchi C, et al. Effects of tetracycline on the filarial worms *Brugia pahangi* and *Dirofilaria immitis* and their bacterial endosymbionts *Wolbachia*. *Int J Parasitol.* 1999;29:357-364.
- Bazzocchi C, Mortarino M, Grandi G, et al. Combined ivermectin and doxycycline treatment has microfilaricidal and adulticidal activity against *Dirofilaria immitis* in experimentally infected dogs. *Int J Parasitol.* 2008;38:1401-1410.
- Benedict MQ, Levine RS, Hawley WA, Lounibos LP. Spread of the tiger: global risk of invasion by the mosquito *Aedes albopictus*. *Vector Borne Zoonotic Dis.* 2007;7:76-85.
- Bouchery T, Lefoulon E, Karadjian G, et al. The symbiotic role of *Wolbachia* in Onchocercidae and its impact on filariasis. *Clin Microbiol Infect.* 2013;19:131-140.
- Boudreaux M, Dillon AR, Ravis WR, et al. Effects of treatment with aspirin or aspirin/dipyridamole combination in heartworm-negative, heartworm infected, and embolized heartworm-infected dogs. *Am J Vet Res.* 1991; 52(12):1992-1999.
- Bowman DD. Heartworms, macrocyclic lactones, and the specter of resistance to prevention in the United States. *Parasit Vectors.* 2012;5:138.

- Bowman DD, Atkins CE. Heartworm biology, treatment, and control. *Vet Clin North Am Small Anim Pract.* 2009;39:1127-1158.
- Bowman DD, Little SE, Lorentzen L, et al. Prevalence and geographic distribution of *Dirofilaria immitis*, *Borrelia burgdorferi*, *Ehrlichia canis*, and *Anaplasma phagocytophilum* in dogs in the United States: Results of a national clinic-based serologic survey. *Vet Parasitol.* 2009;160:138-148.
- Calvert CA. Treatment of heartworm disease with associated severe pulmonary arterial disease. In *Proceedings of the Heartworm Symposium '86*, New Orleans. American Heartworm Society, 1986, pp 125-129.
- Calvert CA, Rawlings CA. Canine heartworm disease. In Fox PR (ed): *Canine and Feline Cardiology*. New York: Churchill Livingstone, 1988, pp 519-549.
- Campbell WC (Ed). *Ivermectin and Abamectin*. New York: Springer-Verlag; 1989, pp 248-250.
- Case JL, Tanner PA, Keister DM, Meo NJ. A clinical field trial of melarsomine dihydrochloride (RM340) in dogs with severe (class 3) heartworm disease. In *Proceedings of the Heartworm Symposium '95*, Auburn, AL. American Heartworm Society, 1995, pp 243-250.
- Christensen BM, Hollander AL. Effect of temperature on vector parasite relationships of *Aedes trivittatus* and *Dirofilaria immitis*. *Proceedings of the Helminthological Society of Washington.* 1978;45:115-119.
- Christensen BM, Rowley WA. Observations on the laboratory biology and maintenance of *Aedes trivittatus*. *Mosquito News.* 1978;38:9-14.
- Courtney CH. Predicting heartworm burdens with a heartworm antigen test kit. *JAAHA.* 1987;23:387-390.
- Courtney CH, Cornell JA. Evaluation of heartworm immunodiagnostic tests. *J Am Vet Med Assoc.* 1990;197:724-729.
- Courtney CH, Zeng Q-Y. Comparison of heartworm antigen test kit performance in dogs having low heartworm burdens. *Vet Parasitol.* 2001;96:317-322.
- Darsie R Jr, Ward R. *Identification and Geographical Distribution of the Mosquitoes of North America, North of Mexico*. University Press of Florida, Gainesville, FL, 2005.
- Dillon AR, Brawner WR, Hanrahan L. Influence of number of parasites and exercise on the severity of heartworm disease in dogs. In *Proceedings of the Heartworm Symposium '95*, Auburn, AL. American Heartworm Society, 1995, p 113.
- Dillon AR, Warner AE, Molina RM. Pulmonary parenchymal changes in dogs and cats after experimental transplantation of dead *Dirofilaria immitis*. In Sol MD, Knight DH (eds): *Proceedings of the Heartworm Symposium*, Auburn, AL. American Heartworm Society, 1995, pp 97-101.
- Dzimianski MT, McCall JW, Mansour AM. The effect of prednisone on the efficacy of melarsomine dihydrochloride against adult *Dirofilaria immitis* in experimentally infected beagles. In *State of the Heartworm '10 Symposium*, Memphis, TN. American Heartworm Society, 2010.
- Dzimianski MT, McCall JW, McTier TL, Raynaud JP. Efficacy of RM 340 compared with thiacetarsamide judged by objective criteria. 1. Controlled laboratory tests in canine models. In *Proceedings of the AAVP 35th Annual Meeting*, San Antonio, TX, 1990, p 51.
- Dzimianski MT, McTier TL, McCall JW, Raynaud JP. Assessment of filaricidal activity of a new filaricide (RM 340) against immature and adult heartworms using experimental canine models. In *Proceedings of the Heartworm Symposium '89*, Washington, DC. American Heartworm Society, 1989, pp 147-153.
- Ernst J, Slocombe JOD. The effect of low temperature on developing *Dirofilaria immitis* larvae in *Aedes triseriatus*. In *Proceedings of the Heartworm Symposium '83*, Orlando, FL. American Heartworm Society, 1983, pp 1-4.
- Fortin JF, Slocombe JOD. Temperature requirements for the development of *Dirofilaria immitis* in *Aedes triseriatus* and *Ae. vexans*. *Mosquito News.* 1981;41:625-633.

- Fukami N, Hagio M, Okano S, Watanabe S. Influence of exercise on recovery of dogs following heartworm adulticide treatment with melarsomine. In *Recent Advances in Heartworm Disease: Symposium '98*, Tampa, FL. American Heartworm Society, 1998, pp 225-227.
- Geary TG, Bourguinat C, Prichard RK. Evidence for macrocyclic lactone anthelmintic resistance in *Dirofilaria immitis*. *Topics Companion Anim Med*. 2011;26:186-192.
- Georgi JR, Georgi ME. Heartworms and other filarids. In *Canine Clinical Parasitology*. Philadelphia, PA: Lea & Febiger, 1992, pp 192-198.
- Gjullin CM, Yates WW, Stage HH. Studies on *Aedes vexans* (Meig.) and *Aedes sticticus* (Meig.) floodwater mosquitoes in the lower Columbia River Valley. *Ann Entomol Soc Am*. 1950;43:262-275.
- Grandi G, Quintavalla C, Mavropoulou A, et al. A combination of doxycycline and ivermectin is adulticidal in dogs with naturally acquired heartworm disease (*Dirofilaria immitis*). *Vet Parasitol*. 2010;169:347-351.
- Grieve RB, Knight DH. Anti-*Dirofilaria immitis* antibody levels before and after anthelmintic treatment of experimentally infected dogs. *J Parasitol*. 1985;71:56-61.
- Guerrero J, McCall JW, Genchi C, et al. Recent advances in heartworm disease. *Vet Parasitol*. 2004;125:105-130.
- Hinman EH, Hurlbut HS. A study of winter activities and hibernation of *Anopheles quadrimaculatus* in the Tennessee Valley. *Am J Trop Med Hyg*. 1940;20:431-446.
- Hirano Y, Kitagawa H, Sasaki Y. Relationship between pulmonary arterial pressure and pulmonary thromboembolism associated with dead worms in canine heartworm disease. *J Vet Med Sci*. 1992;54:897-904.
- Hoerauf A, Mand S, Fischer K, et al. Doxycycline as a novel strategy against bancroftian filariasis-depletion of *Wolbachia* endosymbionts from *Wuchereria bancrofti* and stop of microfilaria production. *Med Microbiol Immunol*. 2003;192:211-216.
- Hoffman J, Miller JR. Reassessment of the role and utility of wind in suppression of mosquito (Diptera: Culicidae) host finding: Stimulus dilution supported over flight limitation. *J Med Entomol*. 2003;40(5):607-614.
- Hoskins JD, Hribernik TN, Kearney MT. Complications following thiacetarsamide sodium therapy in Louisiana dogs with naturally-occurring heartworm disease. *Cornell Vet*. 1985;75:531-539.
- Ishihara K, Kitagawa H, Ojima M, et al. Clinicopathological studies on canine dirofilarial hemoglobinuria. *Jap J Vet Sci*. 1978;40:525-537.
- Ishihara K, Kitagawa H, Sasaki Y. Efficacy of heartworm removal in dogs with dirofilarial hemoglobinuria using flexible alligator forceps. *Jap J Vet Sci*. 1988;50:739-745.
- Jackson RF. The venae cavae syndrome. In Otto G, Jackson RF, Jackson WF (eds): *Proceedings of the Heartworm Symposium 1974*, Auburn, AL. American Heartworm Society, 1974, pp 48-50.
- Jackson RF, Seymour WG, Growney PJ, Otto GF. Surgical treatment of the caval syndrome of canine heartworm disease. *J Am Vet Med Assoc*. 1977;171:1065-1069.
- Kartman L. Factors influencing infection of the mosquito with *Dirofilaria immitis* (Leidy, 1856). *Exp Parasitol*. 1953;2:27-78.
- Keister DM, Dzimianski MT, McTier TL, et al. Dose selection and confirmation of RM 340, a new filaricide for the treatment of dogs with immature and mature *Dirofilaria immitis*. In *Proceedings of the Heartworm Symposium '92*, Austin, TX. American Heartworm Society, 1992, pp 225-229.
- Kitagawa H, Sasaki Y, Ishihara K. Clinical studies on canine dirofilarial hemoglobinuria: relationship between the presence of heartworm mass at the tricuspid valve orifice and plasma hemoglobin concentration. *Jap J Vet Sci*. 1986;48:99-103.
- Knight DH. Guidelines for diagnosis and management of heartworm (*Dirofilaria immitis*) infection. In Bonagura JD (ed): *Kirk's Current Veterinary Therapy XII, Small Animal Practice*. Philadelphia, PA: WB Saunders Co, 1995, pp 879-887.

- Knight DH, Lok JB. Seasonality of heartworm infection and implications for preventive. *Clin Tech Small Anim.* 1998;13:77-82.
- Knott J. A method for making microfilarial surveys on day blood. *Trans R Soc Trop Med Hyg.* 1939;33:191-196.
- Kotani T, Powers KG. Developmental stages of *Dirofilaria immitis* in the dog. *Am J Vet Res.* 1982;43:2199-2206.
- Kozek WJ. What is new in the *Wolbachia/Dirofilaria* interaction. *Vet Parasitol.* 2005;133(2-3):127-132.
- Kozek WJ, Vazquez AE, Gonzalez C Jr, et al. Prevalence of canine filariae in Puerto Rico and the Caribbean. In *Proceedings of the Heartworm Symposium '95*, Auburn, AL. American Heartworm Society, 1995.
- Kramer L, Grandi G, Passeri B, et al. Evaluation of lung pathology in *Dirofilaria immitis* Experimentally infected dogs treated with doxycycline or a combination of doxycycline and ivermectin before administration of melarsomine dihydrochloride. *Vet Parasitol.* 2011;176:357-360.
- Kramer L, Simon F, Tamarozzi F, et al. Is *Wolbachia* complicating the pathological effects of *Dirofilaria immitis* infections? *Vet Parasitol.* 2005;133(2-3):133-136.
- Kramer LH, Tamarozzi F, Morchón R, et al. Immune response to and tissue localization of the *Wolbachia* surface protein (WSP) in dogs with natural heartworm (*Dirofilaria immitis*) infection. *Vet Immunol Immunopathol.* 2005;106:303-308.
- Kume S, Itagaki S. On the life-cycle of *Dirofilaria immitis* in the dog as the final host. *Br Vet J.* 1955;111:16-24.
- Lee ACY, Bowman DD, Lucio-Forster A, et al. Evaluation of a new in-clinic method for the detection of canine heartworm antigen. *Vet Parasitol.* 2011;177:387-391.
- Lichtenfels JR, Pilitt PA, Kotani T, Powers KG. Morphogenesis of developmental stages of *Dirofilaria immitis* (Nematoda) in the dog. *P Helm Soc Wash.* 1985;52:98-113.
- Lok JB, Knight DH. Laboratory verification of a seasonal heartworm transmission model. *Recent Advances in Heartworm Disease: Symposium '98*, Tampa, FL. American Heartworm Society, 1998, pp 15-20
- Löwenberg Neto P, Navarro-Silva MA. Development, longevity, gonotrophic cycle and oviposition of *Aedes albopictus* Skuse (Diptera: Culicidae) under cyclic temperatures. *Neotrop Entomol.* 2004;33:29-33.
- Ludlam KW, Jachowski LA Jr, Otto GF. Potential vectors of *Dirofilaria immitis*. *J Am Vet Med Assoc.* 1970;157:1354-1359.
- Maxwell E, Ryan K, Reynolds C, Pariaut R. Outcome of a heartworm treatment protocol in dogs presenting to Louisiana State University from 2008 to 2011: 50 cases. *Vet Parasitol.* 2014;206:71-77.
- McCall JW. A parallel between experimentally induced canine and feline heartworm disease. In *Proceedings of XVII World Small Animal Veterinary Association World Congress*. Rome, 1992, pp 255-261.
- McCall JW. The safety-net story about macrocyclic lactone heartworm preventives: A review, an update, and recommendations. *Vet Parasitol.* 2005;133:197-206.
- McCall JW, Arther R, Davis W, Settje T. Safety and efficacy of 10% imidacloprid + 2.5% moxidectin for the treatment of *Dirofilaria immitis* circulating microfilariae in experimentally infected dogs. *Vet Parasitol.* 2014b;206:5-13.
- McCall JW, Genchi C, Kramer L, et al. Heartworm and *Wolbachia*: therapeutic implications. *Vet Parasitol.* 2008a;158:204-214.
- McCall JW, Genchi C, Kramer LH, et al. Heartworm disease in animals and humans. In *Rollinson D, Hay SI (eds): Advances in Parasitology*. New York: Academic Press, 2008b, pp 193-285.
- McCall JW, Guerrero J, Roberts RE, et al. Further evidence of clinical prophylactic, retroactive (reach-back) and adulticidal activity of monthly administrations of ivermectin (Heartgard Plus) in dogs experimentally infected with heartworms. In *Recent Advances in Heartworm Disease Symposium '01*. American Heartworm Society, 2001a, pp 198-200.

- McCall JW, Hodgkins E, Varloud, et al. Blocking the transmission of heartworm (*Dirofilaria immitis*) to mosquitoes (*Aedes aegypti*) by weekly exposure for one month to microfilaremic dogs treated once topically with dinotefuran-permethrin-pyriproxyfen. *Parasit Vectors*. 2017a;10(Suppl 2):511.
- McCall JW, Kramer L, Genchi C, et al. Effects of melarsomine dihydrochloride on 2-month-old infections of *Dirofilaria immitis* and *Brugia pahangi* in dogs with dual infections. In *State of the Heartworm '10 Symposium*, Memphis, TN. American Heartworm Society, 2010.
- McCall JW, Kramer L, Genchi C, et al. Effects of doxycycline on early infections of *Dirofilaria immitis* in dogs. *Vet Parasitol*. 2011;176:361-367.
- McCall JW, Kramer L, Genchi C, et al. Effects of doxycycline on heartworm embryogenesis, transmission, circulating microfilaria, and adult worms in microfilaremic dogs. *Vet Parasitol*. 2014a; 206(1-2):5-13.
- McCall JW, Supakordej N, Donoghue AR, et al. Evaluation of the performance of canine heartworm antigen test kits licensed for use by veterinarians and canine heartworm test kits conducted by diagnostic laboratories. In *Recent Advances in Heartworm Disease: Symposium '01*. American Heartworm Society, 2001b, pp 97-104.
- McCall JW, Varloud M, Hodgkins E, et al. Shifting the paradigm in *Dirofilaria immitis* prevention: blocking transmission from mosquitoes to dogs using repellents/insecticides and macrocyclic lactone prevention as part of a multimodal approach. *Parasit Vectors*. 2017b;10(Suppl 2):525.
- McGreevy PB, Theis JH, Lavoipierre MM, Clark J. Studies on filariasis. III. *Dirofilaria immitis*: emergence of infective larvae from the mouthparts of *Aedes aegypti*. *J Helminthol*. 1974;48:221-228.
- McKay T, Bianco T, Rhodes L, Barnett S. Prevalence of *Dirofilaria immitis* (Nematoda: Filarioidea) in mosquitoes from northeast Arkansas, the United States. *J Med Entomol*. 2013;50:871-878.
- McTier TL, McCall JW, Dzimianski MT, et al. Use of melarsomine dihydrochloride (RM 340) for adulticidal treatment of dogs with naturally acquired infections of *Dirofilaria immitis* and for clinical prophylaxis during reexposure for 1 year. *Vet Parasitol*. 1994;55:221-233.
- Mealey KL. Canine ABCB1 and macrocyclic lactones: Heartworm prevention and pharmacogenetics. *Vet Parasitol*. 2008;158:215-222.
- Moise NS. Echocardiography. In Fox PR (ed): *Canine and Feline Cardiology*. New York: Churchill Livingstone, 1988, pp 113-156.
- Moorhead AR, Evans CC, Kaplan RM. A diagnostic algorithm for evaluating cases of potential macrocyclic lactone-resistant heartworm. *Parasit Vectors*. 2017;10(Suppl 2):479.
- Morchón R, Carretón E, González Miguel J, Mellado Hernández I. Heartworm disease (*Dirofilaria immitis*) and their vectors in Europe. New distribution trends. *Front Physiol*. 2012;3.
- Moreno Y, Nabhan JF, Solomon J, et al. Ivermectin disrupts the function of the excretory-secretory apparatus in microfilariae of *Brugia malayi*. *Proc Natl Acad Sci USA*. 2010;107:20120-20125.
- Morini S, Venco L, Fagioli P, Genchi C. Surgical removal of heartworms versus melarsomine treatment of naturally-infected dogs with high risk of thromboembolism. In *Recent Advances in Heartworm Disease: Symposium '98*, Tampa, FL. American Heartworm Society, 1998, pp 235-240.
- Nelson CT. Heartworm disease. In Greene C (ed): *Infectious Diseases of the Dog and Cat*, 4th ed. Elsevier, 2012, pp 865-877.
- Nelson CT. Evaluation of temperature variation in microclimates in multiple U.S. locales and its effect on accuracy of models for prediction of mosquito survival and heartworm transmission. Presented at the American Heartworm Society Triennial Symposium, 2016.
- Nelson CT, Myrick ES, Nelson TA. Clinical benefits of incorporating doxycycline into a canine heartworm treatment protocol. *Parasit Vectors*. 2017;10(Suppl 2):515.
- Orihel TC. Morphology of the larval stages of *Dirofilaria immitis* in the dog. *J Parasitol*. 1961;47:251-262.
- Papich MG, Davidson GS, Fortier LA. Doxycycline concentration over time after storage in a compounded veterinary preparation. *J Am Vet Med Assoc*. 2013;242(12):1674-1678.

- Paul AJ et al. Efficacy of ivermectin against *Dirofilaria immitis* larvae in dogs 30 and 45 days after induced infection. *Am J Vet Res.* 1986;47:883-884.
- Peterson AT, Campbell LP. Global potential distribution of the mosquito *Aedes notoscriptus*, a new alien species in the United States. *J Vector Ecol.* 2015 Jun;40(1):191-4.
- Peterson KM, Chappell DE, Lewis B, et al. Heartworm-positive dogs recover without complications from surgical sterilization using cardiovascular sparing anesthesia protocol. *Vet Parasitol.* 2014; 206:83-85.
- Pratt HD, Moore CD. *Mosquitoes of Public Health Importance and Their Control.* United States Government Printing Office, Washington, DC, 1960.
- Pulliam JD, Seward RL, Henry RT, Steinberg SA. Investigating ivermectin toxicity in Collies. *Vet Med.* 1985;80:33-40.
- Rawlings CA. Acute response of pulmonary blood flow and right ventricular function to *Dirofilaria immitis* adults and microfilaria. *Am J Vet Res.* 1980;41:244-249.
- Rawlings CA. *Heartworm Disease in Dogs and Cats.* Philadelphia: Saunders, 1986.
- Rawlings CA, Bowman DD, Howerth EW, et al. Response of dogs treated with ivermectin or milbemycin starting at various intervals after *Dirofilaria immitis* infection. *Vet Therap Res Appl Vet Med.* 2001;2:193-207.
- Rawlings CA, Keith JC Jr, Losonsky JM, McCall JM. An aspirin-prednisolone combination to modify post adulticide lung disease in heartworm-infected dogs. *Am J Vet Res.* 1984;45:2371-2375.
- Rawlings CA, Raynaud JP, Lewis RE, Duncan JR. Pulmonary thromboembolism and hypertension after thiacetarsamide vs melarsomine dihydrochloride treatment of *Dirofilaria immitis* infection in dogs. *Am J Vet Res.* 1993a;54:920-925.
- Rawlings CA, Tonelli Q, Lewis RE, Duncan JR. Semiquantitative test for *Dirofilaria immitis* as a predictor of thromboembolic complications associated with heartworm treatment in dogs. *Am J Vet Res.* 1993b;54:914-919.
- Rossi MID, Paiva J, Bendas A, et al. Effects of doxycycline on the endosymbiont *Wolbachia* in *Dirofilaria immitis* (Leidy, 1856)—Naturally infected dogs. *Vet Parasitol.* 2010;174:119-123.
- Savadelis MD, Ohmes CM, Hostetler JA, et al. Assessment of parasitological findings in heartworm-infected beagles treated with Advantage Multi® for dogs (10% imidacloprid + 2.5% moxidectin) and doxycycline. *Parasit Vectors.* 2017;10:245
- Scoles GA, Dickson SL. New foci of canine heartworm associated with introductions of new vector species. *Proceedings of the Heartworm Symposium '95*, Auburn, AL. American Heartworm Society. 1995;27-35
- Scoles GA, Dickson SL, Blackmore MS. Assessment of *Aedes sierrensis* as a vector of canine heartworm in Utah using a new technique for determining the infectivity rate. *J Am Mosq Control Assoc.* 1993;9:88-90.
- Slocombe J, Srivastava B, Surgeoner G. The transmission period for heartworm in Canada. In *Proceedings of the Heartworm Symposium '95*, Auburn, AL. American Heartworm Society, 1995, pp 43-48.
- Slocombe JOD, Surgeoner GA, Srivastava B. 1989. Determination of the heartworm transmission period and its used in diagnosis and control. In *Proceedings of the Heartworm Symposium '89*, Charleston, SC. American Heartworm Society, 1989, pp 19-26.
- Taylor AE. The development of *Dirofilaria immitis* in the mosquito *Aedes aegypti*. *J Helminthol.* 1960;34:27-38.
- Taylor MJ, Bandi C, Hoerauf A. *Wolbachia* bacterial endosymbionts of filarial nematodes. *Adv Parasitol.* 2005;60:245-284.
- Terrell S. Heartworm in Alaska: Prevalence in domestic dogs and wild canids. In *Recent Advances in Heartworm Disease Symposium '98*, Tampa, FL. American Heartworm Society, 1988, pp 83-86.
- Townson S, Tagboto S, McGarry HF, et al. *Onchocerca* parasites and *Wolbachia* endosymbionts: evaluation of a spectrum of antibiotic types for activity against *Onchocerca gutturosa* in vitro. *Filaria J.* 2006;5:4.

- Vatta AF, Dzimianski M, Storey BE, et al. Ivermectin-dependent attachment of neutrophils and peripheral blood mononuclear cells to *Dirofilaria immitis* microfilariae in vitro. *Vet Parasitol.* 2014;206:38-42.
- Velasquez L, Blagburn BL, Duncan-Decoq R, et al. Increased prevalence of *Dirofilaria immitis* antigen in canine samples after heat treatment. *Vet Parasitol.* 2014;206:67-70.
- Venco L. Diagnosis of vena cava syndrome. *Veterinaria.* 1993;7:11-18.
- Venco L, Genchi C, Vigevani Colson P, Kramer L. Relative utility of echocardiography, radiography, serologic testing and microfilariae counts to predict adult worm burden in dogs naturally infected with heartworms. In *Recent Advances in Heartworm Disease Symposium '01*. American Heartworm Society, 2001, pp 111-124.
- Venco L, McCall JW, Guerrero J, Genchi C. Efficacy of long-term monthly administration of ivermectin on the progress of naturally acquired heartworm infections in dogs. *Vet Parasitol.* 2004;124:259-268.
- Vezzoni A, Genchi C, Raynaud JP. Adulticide efficacy of RM 340 in dogs with mild and severe natural infections. In *Proceedings of the Heartworm Symposium '92*. Austin, TX. American Heartworm Society, 1992, pp 231-240.
- Wang LC. Comparison of a whole-blood agglutination test and an ELISA for the detection of the antigens of *Dirofilaria immitis* in dogs. *Ann Trop Med Parasitol.* 1998;92:73-77.
- Yoon WK, Choi R, Lee SG, et al. Comparison of 2 retrieval devices for heartworm removal in 52 dogs with heavy worm burden. *J Vet Intern Med.* 2013;27(3):469-473.



**AMERICAN
HEARTWORM
SOCIETY**
EST.1974

These guidelines are based on the latest information on heartworm disease. In keeping with the objective of the Society to encourage adoption of standardized procedures for the diagnosis, treatment, and prevention of heartworm disease, they will continue to be updated as new knowledge becomes available.