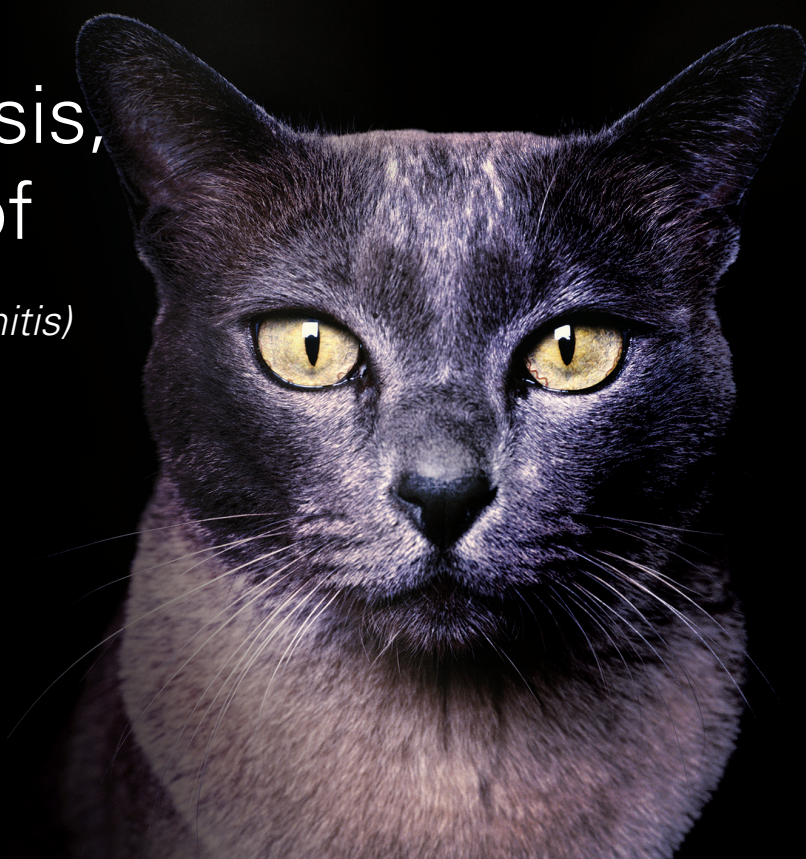

Current Feline Guidelines for the
Prevention, Diagnosis,
and Management of
Heartworm (*Dirofilaria immitis*)
Infection in Cats



AMERICAN
HEARTWORM
SOCIETY
EST. 1974



Thank You to Our Generous Sponsors:



Boehringer
Ingelheim



zoetis



IDEXX
LABORATORIES



MERCK
Animal Health

Current Feline Guidelines for the
**Prevention, Diagnosis,
and Management of
Heartworm** (*Dirofilaria immitis*)
Infection in Cats



CONTENTS

Click on the links below to navigate to each section.

Preamble 2

EPIDEMIOLOGY 2
Figure 1. Urban heat island profile.

BIOLOGY OF FELINE HEARTWORM INFECTION 3
Figure 2. The heartworm life cycle.

PATHOPHYSIOLOGY OF FELINE HEARTWORM DISEASE 5
Figure 3. Microscopic lesions of HARD in the small pulmonary arterioles.
Figure 4. Microscopic lesions of HARD in the alveoli.

PHYSICAL DIAGNOSIS 6
Clinical Signs and Findings

DIAGNOSTIC TESTING 6
Microfilariae
Serology
Thoracic Radiography
Echocardiography
Necropsy Confirmation
Figure 5. Summary of feline heartworm diagnostics.
Table 1. Interpretation of heartworm diagnostic procedures and tests in cats.

TREATMENT 10
Medical Options
Surgical Options
Additional Considerations for Adulticide Therapy
 Wolbachia
 Surveillance of Infected Cats

PREVENTION 11
Drugs
Serologic Testing

REFERENCES 13

Prepared and approved by the Executive Board of the American Heartworm Society

(Officers: **Dr. Stephen Jones**, President; **Dr. Wallace Graham**, Past President; **Dr. Cristiano von Simson**, Vice President; **Dr. Robert Stannard**, Secretary-Treasurer; **Dr. Doug Carithers**, Editor; **Dr. Patricia Payne**, **Dr. Chris Rehm**, **Dr. Charles Thomas Nelson**, **Dr. Martha Smith-Blackmore**, **Dr. Elizabeth Clyde and**, **Dr. Bianca Zaffarano** Board Members; **Dr. Matthew Miller**, Symposium Chair; **Dr. Clarke Atkins**, Symposium Co-Chair; **Dr. John McCall**, Co-Editor; **Dr. Mike Loenser** and **Dr. Tony Rumschlag**, Ex Officio Members.

References added October 2015 by **Christopher Evans**, MS, Research Professional II, Department of Infectious Diseases, College of Veterinary Medicine, University of Georgia.

Preamble

These guidelines are a living document and are revised periodically based on information presented at the American Heartworm Society's Triennial Symposium, new research, and additional clinical experience. This version supersedes previous editions and has been peer reviewed by independent experts. The recommendations for the prevention, diagnosis, and management of heartworm infection in dogs can be found in a companion canine document (available on the [AHS website](#)).

EPIDEMIOLOGY

Heartworm infection has been diagnosed around the globe, including all 50 of the United States. In the United States, its territories and protectorates, heartworm is considered at least regionally endemic in each of the contiguous 48 states, Hawaii, Puerto Rico, U.S. Virgin Islands, and Guam (Bowman and Atkins, 2009; Kozek et al, 1995; Ludlam et al, 1970). Heartworm transmission has not been documented in Alaska; however, there are regions in central Alaska that have mosquito vectors and climate conditions to support the transmission of heartworms for brief periods (Darsie and Ward, 2005; Slocombe et al, 1995; Terrell, 1998). Thus, the introduction of microfilaremic dogs or wild canids could set up a nidus of infection for local transmission of heartworm in this state. Such relocation of microfilaremic dogs and expansion of the territories of microfilaremic wild canids in other areas of the United States continue to be important factors contributing to further dissemination of the parasite, as the ubiquitous presence of one

or more species of vector-competent mosquitoes makes transmission possible wherever a reservoir of infection and favorable climatic conditions co-exist (Levy et al, 2007, 2011). Change in any of these factors can have a significant effect on the transmission potential in a specific geographic location.

Environmental changes, both natural climatic change and those created by humans, and animal movement have increased heartworm infection potential. Commercial and residential real estate development of non-endemic areas and areas of low incidence has led to the resultant spread and increased prevalence of heartworms by altering drainage of undeveloped land and by providing water sources in new urban home sites. In the western United States, irrigation and planting of trees has expanded the habitat for *Aedes sierrensis* (western knot hole mosquito), the primary vector for transmission of heartworms in those states (Scoles et al, 1993). *Aedes albopictus* (Asian tiger mosquito), which was introduced into the Port of Houston in 1985, has now spread northward, approaching Canada (Scoles and Dickson, 1995), and isolated populations have been identified in areas in the western states. This urban-dwelling mosquito is able to reproduce in small containers such as flowerpots (Benedict et al, 2007). Urban sprawl has led to the formation of "heat islands," as buildings and parking lots retain heat during the day (Figure 1), creating microenvironments with potential to support the development of heartworm larvae in mosquito vectors during colder months, thereby lengthening the transmission season (Morchón et al, 2012).

As vectors expand their territory, the number of animals infected will continue to increase. A pivotal prerequisite for heartworm transmission is a climate that provides adequate temperature and humidity to support a viable mosquito population, and also sustain sufficient heat to allow maturation of ingested microfilariae into the infective, third-stage larvae (L3) within this intermediate host. It has been shown that maturation of larvae, within three mosquito species, ceases at temperatures below 57°F (14°C) (Christensen and Hollander, 1978; Fortin and Slocombe, 1981). Heartworm transmission does decrease in winter months but the presence of microenvironments in urban areas suggests that the risk of heartworm transmission never reaches zero. Furthermore, some species of mosquitoes overwinter as adults. While heartworm larval development in these mosquitoes may cease in cool

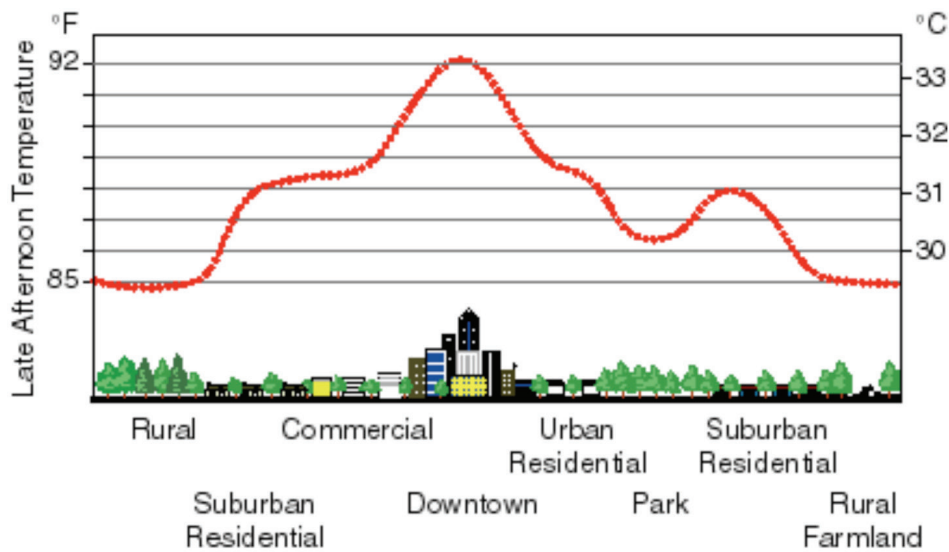


Figure 1. Sketch of an urban heat island profile. From <http://eetd.lbl.gov/eatlsland/HighTemps/>

temperatures, development quickly resumes with subsequent warming (Ernst and Slocombe, 1983).

The length of the heartworm transmission season in the temperate latitudes is critically dependent on the accumulation of sufficient heat to incubate larvae to the infective stage in the mosquito (Knight and Lok, 1998; Lok and Knight, 1998). The peak months for heartworm transmission in the Northern Hemisphere are typically July and August. Models predict that heartworm transmission in the continental United States is limited to 6 months or less above the 37th parallel at approximately the Virginia–North Carolina state line (Guerrero et al, 2004). While model-based predictions of transmission using climatic data are academically appealing, they typically fail to consider several potentially important factors, such as influence of microclimate, unique biological habits and adaptations of the mosquito vectors, variations in time of larval development and mosquito life expectancy, year-to-year temperature fluctuations, and global climate change. Predictive risk maps assume that mosquito vectors live for only one month; however, several significant mosquito vectors live and breed for much longer periods, including *Aedes albopictus* (3 months) (Löwenberg Neto and Navarro-Silva, 2004), *Aedes sticticus* (3 months) (Gjullin et al, 1950), *Ochlerotatus* (formerly *Aedes*) *trivittatus* (2 months) (Christensen and Rowley, 1978), *Aedes vexans* (2 months) (Gjullin et al, 1950), and *Ochlerotatus* (formerly *Aedes*) *canadensis* (several months) (Pratt and Moore, 1960). There are also documented cases of hibernating *Anopheles quadrimaculatus* surviving for 4 to 5 months (Hinman and Hurlbut, 1940), so the predictive risk maps likely reflect a shorter

transmission season than actually exists.

Once a reservoir of microfilaremic domestic and wild canids is established beyond the reach of veterinary care, the ubiquitous presence of one or more species of vector competent mosquitoes makes transmission possible and eradication becomes improbable.

BIOLOGY OF FELINE HEARTWORM INFECTION

Significant differences exist between feline heartworm disease and its classical canine counterpart and these are consistent with characteristics of partially adapted host–parasite relationships. Although cats are susceptible hosts, they are more resistant to infection with adult *Dirofilaria immitis* than are dogs. When dogs not previously exposed to heartworms are injected with 100 L3 larvae, an average of 60 adult worms develop in almost 100% of the dogs (Blagburn et al, 2011); in 106 experimentally infected cats, however, 79% of the cats had 1 or more worms and 70% had 2 or more worms with an average of 6 per infected cat and a median of 3 heartworms per cat (McCall et al, 1992, Dillon et al, 2007, McCall, unpublished data). These L3 larvae molt to L4 and juvenile worm (immature adult) with some loss along the way but there is a very high mortality rate of the juvenile worms as they reach the lungs 3 to 4 months after infection. Most heartworm infections in cats are comparatively light and consist of less than six adult worms (Genchi et al, 1992b). Although much heavier infections occur occasionally, usually only one or two worms are present, and approximately one third of these consist of worms of the same sex (McTier et al, 1992; Ryan et al, 1995). Nevertheless, because of their relatively small body size, cats with

only a few worms are still considered to be heavily infected in terms of parasite biomass. Some clinical surveys and data from experimentally infected cats have documented a slight preponderance of infection in male cats, but it has not been determined conclusively that male cats are at greater risk (Guerrero et al, 1992; Kramer and Genchi, 2002). No sex predilection for anti-*D immitis* host antibody seropositivity has been proven within populations of naturally exposed cats, nor has a preference by vector mosquitoes for either sex, although some data suggest trends for each toward female cats (Atkins et al, 2000; Fernandez et al, 2010). Host preference by some of the most abundant vectors does favor the dog and may contribute to the lower prevalence of infection in cats (Di Sacco et al, 1992; Genchi et al, 1992a). The *Culex* spp mosquito, which is the most common species in many urban areas, feeds on both cats and dogs without preference (Genchi et al, 1992a).

The true prevalence of heartworm infection in cats is probably understated due to diagnostic limitations,

and the greater tendency of cats to exhibit only transient clinical signs or die without confirmation of infection. Necropsy surveys of shelter cats have placed the prevalence of adult heartworm infections at 5% to 15% of the rate in unprotected dogs in a given area (Ryan and Newcomb, 1995). Circulating microfilariae are seldom found in infected cats (Browne et al, 2005). When microfilariaemias do develop in cats, they appear only about one week later than in dogs (195 days post infection at the earliest) and seldom persist beyond 228 days post infection (McCall et al, 1992). Heartworms transplanted from cats are capable of resuming production of circulating microfilariae in dogs (personal communication, JW McCall, 2014); thus it appears that feline infections become occult due to host immune-mediated clearance of the microfilariae and perhaps a reversible suppression of microfilariae production.

There are other indications that the cat is an imperfect host for heartworms. Aberrant migration occurs more frequently in cats than in dogs (McCall

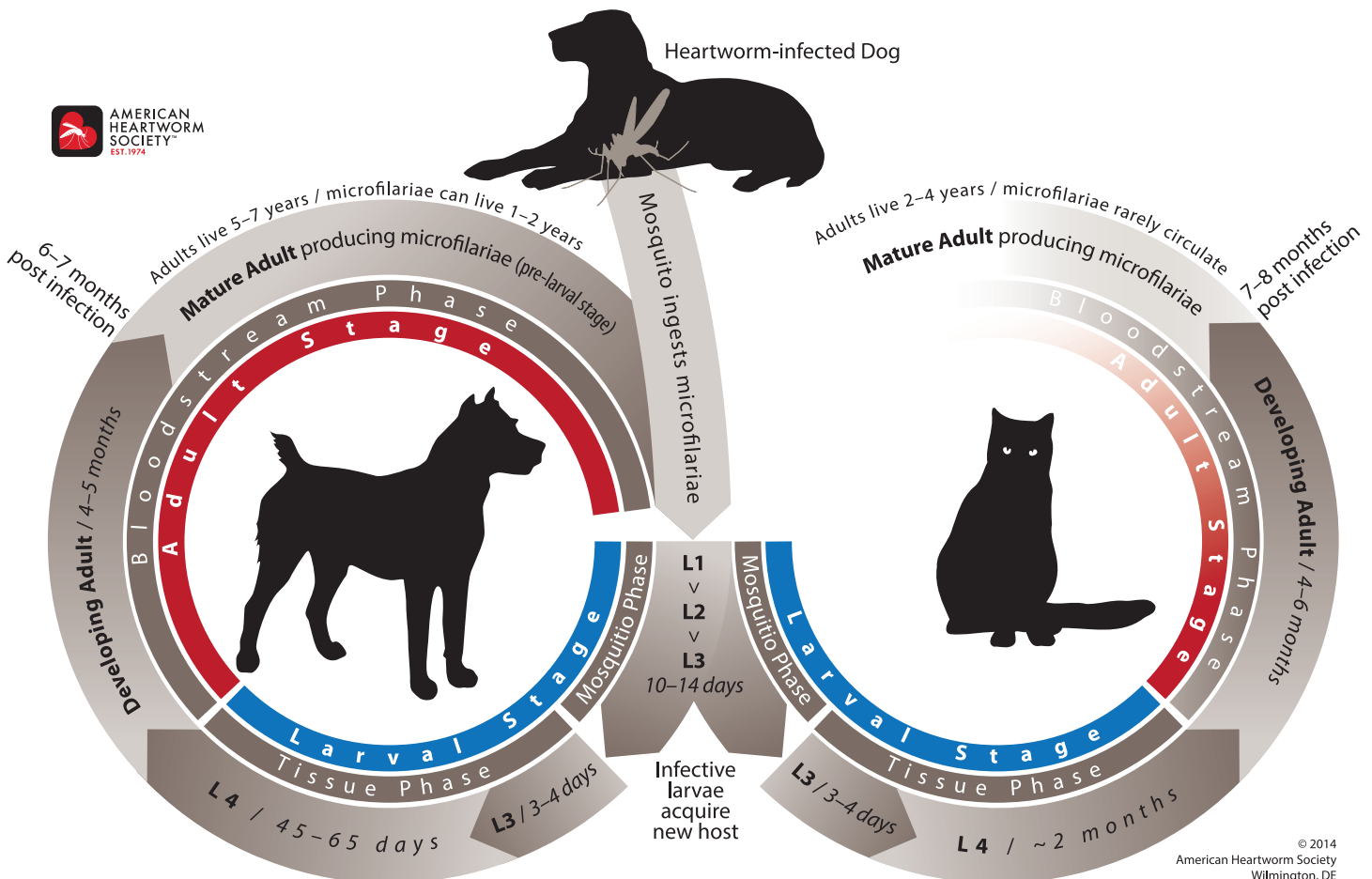


Figure 2. The heartworm life cycle in cats (right).

et al, 1992). Although uncommon, heartworms are found disproportionately often in the body cavities, systemic arteries, and central nervous system of cats. Additionally, the life span of the parasite in cats is thought to be 2 to 4 years, which is considerably shorter than that in dogs (Figure 2) (Genchi et al, 2008; McCall et al, 1992). Nevertheless, heartworms are capable of causing severe disease in cats.

PATHOPHYSIOLOGY OF FELINE HEARTWORM DISEASE

The clinical importance of heartworms is amplified in cats because even a small number of heartworms are potentially life-threatening. Although live adult worms in the pulmonary arteries cause a local arteritis, some cats never manifest clinical signs. When signs are evident, they usually develop during two stages of the disease: 1) arrival of heartworms in the pulmonary vasculature and 2) death of adult heartworms (Dillon, 1998; McCall et al, 2008; Holmes et al, 1992). The first stage coincides with the arrival of immature adult worms in the pulmonary arteries and arterioles approximately 3 to 4 months post infection. These early signs are due to an acute vascular and parenchymal inflammatory response to the newly arriving worms and the subsequent death of most of these same worms (Dillon et al, 2007). This initial phase is often misdiagnosed as asthma or allergic bronchitis but in actuality is part of a syndrome known as *heartworm-associated respiratory disease* (HARD) (Nelson et al, 2007; Blagburn and Dillon, 2007). Clinical signs associated with this acute phase subside as the worms mature but demonstrable histopathologic lesions are evident even in those cats that clear the infection (Browne et al, 2005). The most notable microscopic lesion is occlusive medial hypertrophy of the

small pulmonary arterioles (Figure 3), but other changes are also noted in the bronchi, bronchioles, alveoli (Figure 4), and pulmonary arteries. Once the pulmonary infection is established, evidence suggests that live heartworms are able to suppress immune function (González-Miguel et al, 2010; Simón et al, 2001). This allows many cats to tolerate their infection without apparent ill effects—until the mature worms begin to die, which initiates the second stage of disease expression. The degenerating parasites result in pulmonary inflammation and thromboembolism, which often leads to fatal acute lung injury (Atkins et al, 2000; McCall et al, 2008). Such reactions in cats can occur even in single-worm infections as the result of the death of that worm (Dillon et al, 2008). It has also been shown that the death of pre-cardiac stages (L3 and L4) can lead to smooth muscle hypertrophy of pulmonary arterioles and increases in pulmonary interstitial myofibrocytes. Cats that are on heartworm preventive prior to infection, however, did not exhibit any significant pathologic changes.

In dogs, the caval syndrome (dirofilarial hemoglobinuria) results partly from large numbers of heartworms relocating to the cavae and right atrioventricular junction, interfering with tricuspid valve function. Caval syndrome occurs rarely in cats because infections are usually light; however, even one or two worms may cause tricuspid regurgitation and resultant heart murmur (Bowman and Atkins, 2009).

Arterial intimal proliferation resembling the characteristic heartworm arteritis found in dogs also develops in the major lobar and peripheral pulmonary arteries of cats. Because heartworm infections in cats usually have a small number

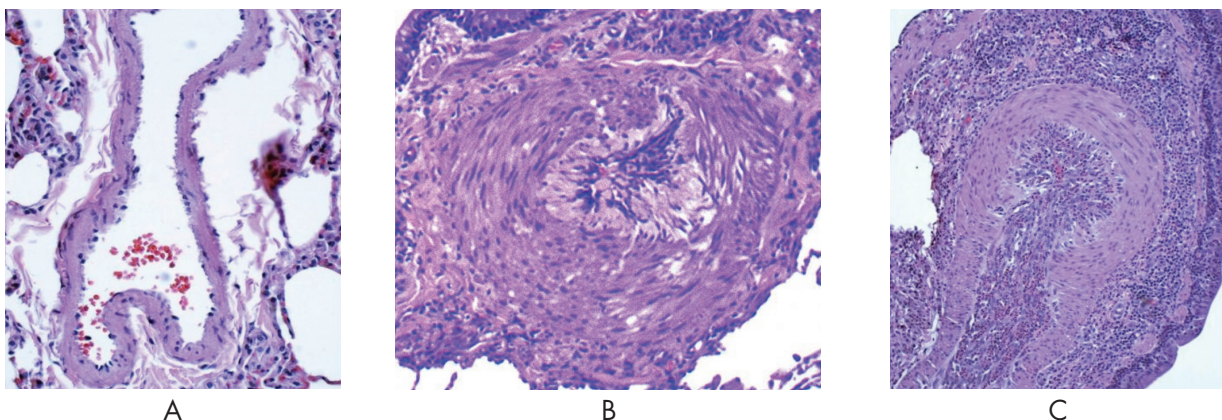


Figure 3. Small pulmonary arterioles. A, Adult heartworm and antibody (Ab) negative. B, Adult heartworm negative and antibody positive. C, Adult heartworm positive.

of worms and are of relatively short duration, these lesions are localized and ordinarily fail to cause sufficient obstruction to produce clinically significant pulmonary hypertension. Consequently, right ventricular hypertrophy and right heart failure are less common in heartworm-infected cats than in dogs. Even when narrowing of a lumen is compounded by worm-induced thrombosis, bronchopulmonary collateral circulation usually is adequate to prevent infarction of the lung (Dillon et al, 1995).

PHYSICAL DIAGNOSIS

Clinical Signs and Physical Findings

Many cats tolerate their infection without any noticeable clinical signs, or with signs manifested only transiently. Clinical signs associated with feline heartworm disease may be only a vague malaise or can consist of predominantly respiratory, gastrointestinal (eg, emesis), or occasionally neurologic manifestations, either chronically or acutely. Signs of chronic respiratory disease such as persistent tachypnea, intermittent coughing, and increased respiratory effort are most common. A systolic heart murmur may be present in cats when worms reside in the right atrioventricular junction interfering with tricuspid valvular function. Anorexia and weight loss occur in some cats. Intermittent vomiting unrelated to eating is reported frequently and in endemic areas when no other cause is evident should raise suspicion of heartworm infection. Other abnormalities, such as ascites, hydrothorax, chylothorax, pneumothorax, ataxia, seizures, and syncope, have been reported but are uncommon. A peracute syndrome consisting of some combination of signs including respiratory distress, ataxia, collapse, seizures, hemoptysis, or sometimes sudden death may arise without warning (Atkins et al, 2000; Dillon, 1984; Dillon et al, 1996, 1997a,b; McCall et al,

2008).

DIAGNOSTIC TESTING

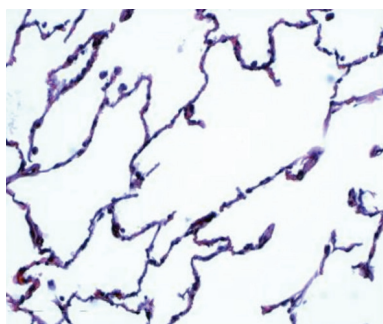
Heartworm infection in cats is a more elusive diagnosis than in dogs and can be overlooked easily. A conscious awareness of its existence is critical. A willingness to pursue this high index of suspicion frequently entails application of multiple diagnostic tests, some of which may need to be repeated on several occasions. Of these, heartworm serology, thoracic radiography, and echocardiography are the most useful methods of clinical confirmation (Dillon et al, 1998).

Microfilariae

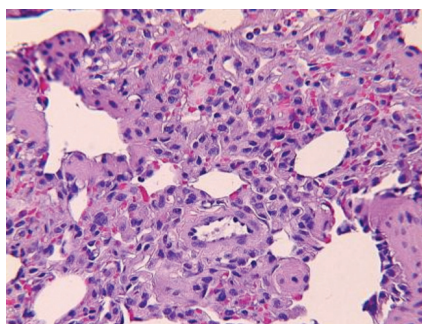
Cats are seldom microfilaremic when examined. In the Americas, only *Dirofilaria immitis* microfilariae have been identified in cats but in northern Italy, microfilariae of *Dirofilaria repens* also have been identified (Genchi et al, 1992b, 1993). Since few microfilariae are ever present, the chances of finding them are improved by using concentrations techniques (modified Knott or millipore filter).

Serology

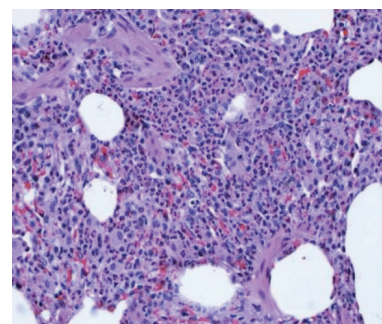
Interpretation of antibody and antigen test results is complicated and a thorough understanding of the limitations of both tests is necessary in order to use these assays in a clinical setting with any confidence. The antigen test is the “gold standard” in diagnosing heartworms in dogs but because unisex infections consisting of only male worms or symptomatic immature infections are more common in cats, none of the presently available antigen tests can be relied upon to rule out heartworm disease in cats. The current generation of heartworm antigen tests identify most “occult” infections (adult worms present but no circulating microfilariae) consisting of at least one mature female worm and are nearly



A



B



C

Figure 4. Alveolus, A, Adult heartworm and antibody (Ab) negative. B, Adult heartworm negative and antibody positive. C, Adult heartworm positive

100% specific (Levy, 2007). In the cat, detectable antigenemia develops at about 5.5 to 8 months post infection (McCall et al, 1998; Stewart et al, 1992). Necropsy surveys of shelter cats have shown that 50% to 70% of infected cats have at least one female worm (Berdoulay et al, 2004; Snyder et al, 2000). False-negative test results occur most commonly when infections are light, female worms are still immature, only male worms are present, and/or the test kit instructions have not been followed (Genchi et al, 1998; McCall et al, 1998). There are also documented cases of antigen-antibody complexes interfering with antigen testing resulting in false-negative tests. Laboratory studies have shown that heating the sample test-tube to 104°C for 10 minutes will break these complexes down, releasing any antigen, resulting in more accurate test results (Little et al, 2014). The routine heating of blood samples IS NOT RECOMMENDED at this time as this is contrary to the label instructions for these tests. It also could interfere with the results of combination tests that include an antibody test for detection of other infectious agents. Due to this and other mentioned considerations, heartworm test results should only be recorded as “positive” or “no antigen detected” (NAD) and should not be written as “negative.”

Antibody tests have the advantage of being able to detect infection as early as 2 months post infection. (McCall et al, 1995). Antibody tests do not offer an indication of the continued existence of an infection, however, just that an infection occurred. Initial research reported the sensitivity and specificity of the feline antibody tests to be as high as 98% in experimentally infected cats with adult worms. (Bestul et al, 1998; McCall et al, 1992; Piché et al, 1998; McCall, 2001). Necropsy surveys of naturally infected cats from shelters, however, have indicated a lower sensitivity ranging from 32% to 89% (Berdoulay et al, 2004; Snyder et al, 2000; Nelson and Self, 1998). The different antibody tests vary in their sensitivity to each stage of larval development, thus discordant results between test methods are common. In a necropsy survey in which six different antibody tests were evaluated, 21 of 31 heartworm-infected cats were negative on at least one antibody test (Snyder et al, 2000). These tests were performed on postmortem samples, which may have some effect on the sensitivity; but in another necropsy survey involving 10 heartworm positive cats, 50% were antibody negative on antemortem samples (Nelson and Self, 1998). A third report of 50 clinical cases from a university referral center had a 14% antibody false-negative

rate (Atkins et al, 2000). These four studies reported a wide range in sensitivity; to understand the differences, the population tested and the timing of the test must be examined. In the first study on experimentally infected cats, 50 to 100 L3 were injected into heartworm-naïve cats and the cats were followed for 6 months. This is a much larger challenge than occurs in nature and no data are available on whether the antibody level will decrease over the expected 2- to 4-year life span of an adult worm in a naturally infected cat. The two necropsy studies represent cat populations more typical of those encountered in clinical practice. In the last study from a university referral center, 72% of the cats had clinical signs of disease. Limited evidence from these studies suggest that the antibody level in cats decreases with time as the parasite matures and that heartworm-infected cats with clinical signs are more likely to be antibody positive than asymptomatic infected cats. Necropsy studies of shelter cats indicate a distinct correlation to antibodies and occlusive medial hypertrophy of substantial numbers of small pulmonary arterioles. These pathologic changes are evident in 79% of necropsy-confirmed adult worm infections and 50% of adult heartworm-negative but antibody-positive cats (Browne et al, 2005). These findings have been confirmed in a study utilizing an experimental model and are significant as they indicate pulmonary disease occurs even in those cats that do not develop adult worm infections (Blagburn and Dillon, 2007; Dillon et al, 2014). In the model cats were infected with 100 L3 and were then treated with ivermectin at 150 µg/kg every 2 weeks starting at day 84 post infection to abbreviate the infection. The study revealed 50% of the cats were antibody negative 8 months later when necropsied. These cats developed radiographic and histopathologic changes indicative of HARD. A second group of cats using the same protocol but necropsied 16 months later were all antibody negative even though radiographic and histopathologic changes could still be detected. Additional studies have shown that precardiac stages of *D immitis* also elicit pathology in bronchial, bronchiole, alveolar-interstitial, and pulmonary arteries. It has been shown that cats placed on selamectin or moxidectin heartworm preventives prior to infection with L3 had significantly fewer pulmonary lesions.

Correct interpretation of antibody test results requires additional information and thoughtful analysis. When infection with adult female worms actually exists, however, antigen tests are more

reliable than generally credited. Since both juvenile and adult worms are capable of causing clinical disease in the cat, both antibody and antigen tests are useful tools and when used together increase the probability of making appropriate diagnostic decisions.

Thoracic Radiography

Independent of serologic test results, radiography may provide strong evidence of feline heartworm disease and is valuable for assessing the severity of disease and monitoring its progression or regression. The most characteristic radiographic features of heartworm disease in cats, as in dogs, are a sometimes subtle enlargement of the main lobar and peripheral pulmonary arteries, characterized by loss of taper, and sometimes tortuosity and truncation in the caudal lobar branches (Brawner et al, 1998; Donahoe et al, 1976a,b; Schafer and Berry, 1995). These vascular features are visualized best in the ventrodorsal view and may be visible only in the right caudal lobar artery, where heartworms are found most often. The characteristic morphology of the pulmonary arteries in infected cats, unlike dogs, tends to normalize and may disappear completely, leaving no residual evidence of infection (Selcer et al, 1996). Enlargement of the main pulmonary artery segment may occur in heavily infected cats but is not a reliable marker because most cats do not develop pulmonary hypertension and because the main pulmonary artery is obscured by the cardiac silhouette. The cardiac silhouette itself is seldom enlarged. A bronchointerstitial lung pattern that may clear spontaneously within a few months is a common secondary feature suggestive of, but not unique to, feline heartworm disease. Other less commonly associated pulmonary findings include hyperinflation of the lungs with flattening of the diaphragm, focal parenchymal radiodensities, consolidated lung lobes, pleural effusion, and pneumothorax (Schafer and Berry, 1995; Selcer et al, 1996). In some cases of feline heartworm disease, thoracic radiographs provide no evidence of infection (Selcer et al, 1996).

Radiographic features suggestive of feline heartworm disease can be found in about half of the cats suspected of being infected based on historical and physical signs. Also, about half of those cats with pulmonary arterial enlargement indicative of feline heartworm disease are antibody positive (Brawner et al, 1998). Temporal differences in the development of the parasite, host

immune responses and organic disease, as well as spontaneous regression of lesions, may account for discrepancies between radiographic, clinical and serologic findings.

Infection with *Toxocara cati* and *Aelurostrongylus* species can cause similar radiographic patterns and must be considered in a differential diagnosis (Browne et al, 2005; Mackenzie, 1960; Swerczek et al, 1970; Dillon et al, 2013).

Echocardiography

The chambers of the right side of the feline heart can be thoroughly interrogated by two-dimensional ultrasonography. Limited access also can be gained to the main pulmonary artery and a long segment of the right and a short portion of the left pulmonary arteries (Venco et al, 1998b). Although heartworms are found most often in the main and right lobar branch of the pulmonary artery, it is necessary to methodically probe all of these locations because worms in a typical light infection may occupy only one or two sites and may escape detection. The body wall of an adult heartworm is strongly echogenic and produces short, segmented, parallel linear artifacts where the imaging plane transects the parasite's body, producing the signature signs of live worms (Selcer et al, 1996). Sometimes dead heartworms can be recognized by collapse of the parallel sides of the body wall. An adult heartworm is relatively long compared with the length of the pulmonary arteries in cats. Therefore, there is a better chance in cats than in dogs of finding heartworms extending from peripheral branches into proximal segments where they can be visualized (Atkins et al, 1998). An experienced sonographer has a very good chance of making a definitive diagnosis in cats that are actually infected with adult heartworms, particularly when there are several worms (DeFrancesco et al, 2001; Genchi et al, 1998). In suspected cases, the high specificity of this examination generally allows for confirmation of heartworm infection of at least 5 months' duration (Selcer et al, 1996). Quantification of worm burden is, nevertheless, difficult because the potential serpentine positioning allows echo beams to transect the worm in multiple sites, giving multiple echo images and potentially overestimating worm burden.

Necropsy Confirmation

Making an antemortem diagnosis of heartworm infection may be difficult and thus necropsy confirmation should be attempted in cats suspected

Table 1. Interpretation of Heartworm Diagnostic Procedures and Tests in Cats

| Test | Brief Description | Result | Interpretation | Limitations |
|----------------------|---|--|---|---|
| Antibody Test | Detects antibodies produced by the cat in response to presence of heartworm larvae. May detect infections as early as 8 weeks post transmission by mosquito | Negative | Lower index of suspicion | Antibodies confirm infection with heartworm larvae, but do not confirm disease causality. |
| | | Positive | Increasing index of suspicion; 50% or more cats will have pulmonary arterial disease; confirms cat is at risk | |
| Antigen Test | Detects antigen produced by the adult female heartworm or from the dying male (>5) or female heartworms | Negative | Lower index of suspicion | Immature or male-only worm infections are rarely detected. |
| | | Positive | Confirms presence of heartworms | |
| Thoracic Radiography | Detects vascular enlargement (inflammation caused by juvenile worms and, later, hypertrophy), pulmonary parenchymal inflammation, and edema [the latter only in acute respiratory distress syndrome (ARDS)-like syndrome] | Normal | Lower index of suspicion | Radiographic signs are subjective and affected by clinical interpretation. |
| | | Signs consistent with feline heartworm disease | Enlarged arteries greatly increase index of suspicion | |
| Echocardiography | Detects echogenic walls of the immature or mature heartworm residing in the lumen of the pulmonary arterial tree, if within the visual window of the ultrasound | No worms seen | No change to index of suspicion | Ultrasonographer experience with heartworm detection appears to influence accuracy rate. |
| | | Worms seen | Confirms presence of heartworms in the structure | |

Note: In the cat, no single test will detect all heartworm cases. While the antigen tests are highly specific for detecting adult heartworm antigen, they will not detect infections with only live male worms. The clinician must use a combination of test results to determine the likelihood of heartworm disease as the etiology of the cat’s symptoms.

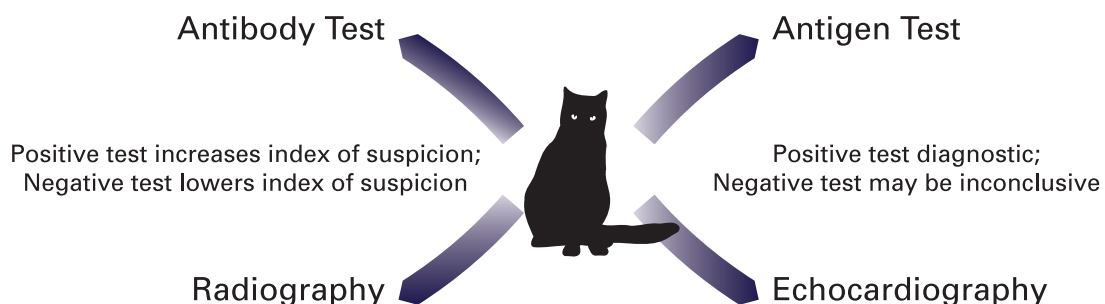


Figure 5. Summary of feline heartworm diagnostics

of dying of the disease or in which the cause of death is unexplained. A thorough search of the venae cavae, right side of the heart, and pulmonary arteries must be performed because one or two worms easily can be overlooked, particularly if immature, dead, or fragmented (Atkins et al, 1998; Genchi et al, 1998; Levy, 2007; McCall et al, 1992, 1995; Atkins et al, 2008). Special attention should be paid to examining the distal extremities of the pulmonary arteries as any dead worms would be forced and compressed, by blood flow, into the most distal and smallest possible space (Miller et al, 1998). Because heartworms occasionally are restricted to ectopic sites, the systemic arteries, body cavities, and, if neurologic signs were present, the brain and spinal canal should also be examined thoroughly (Snyder et al, 2000).

Feline heartworm diagnostics are illustrated in Figure 5 and heartworm diagnostic procedures and tests are summarized in Table 1.

TREATMENT

Medical Options

If a cat displays no overt clinical signs despite radiographic evidence of pulmonary vascular/interstitial lung disease consistent with feline heartworm disease, it may be prudent to allow time for a spontaneous cure to occur. The course of infection in these subclinical cases can be monitored periodically at 6- to 12-month intervals by repeat antibody and antigen testing and thoracic radiography. In those cats destined to recover, regression of radiographic signs and especially seroconversion of a positive antigen test to negative status provide evidence that the period of risk probably has passed (Genchi et al, 2008).

Prednisone in diminishing doses often is effective medical support for infected cats with radiographic evidence of lung disease whether or not they appear ill. Prednisone also should be initiated whenever antibody- and/or antigen-positive cats display clinical signs. An empirical oral regimen is 2 mg/kg body weight/day, declining gradually to 0.5 mg/kg every other day by 2 weeks and then discontinued after an additional 2 weeks. At that time the effects of treatment should be reassessed based on the clinical response and/or thoracic radiography. This treatment may be repeated in cats with recurrent clinical signs.

Cats that become acutely ill need to be stabilized promptly with supportive therapy appropriate for treating shock. Depending on the circumstances,

this may include intravenous corticosteroids, balanced electrolyte solutions, bronchodilators, and oxygen via intranasal catheter or closed cage. Diuretics are inappropriate, even for infected cats with severe interstitial or patchy alveolar lung patterns. Aspirin and other nonsteroidal anti-inflammatory drugs (NSAIDs) have failed to produce demonstrable benefit and actually may exacerbate the parenchymal pulmonary disease (Boudreaux et al, 1991; Rawlings, 1990).

Adulticide administration is considered the treatment of last resort for cats in stable condition that continue to manifest clinical signs that are not controlled by empirical corticosteroid therapy. There is insufficient experience with melarsomine dihydrochloride at this time; thus melarsomine is not recommended for use in cats. Preliminary data suggests that melarsomine is toxic to cats at doses as low as 3.5 mg/kg (Goodman, 1996; McLeroy, 1998).

Ivermectin at a dose of 24 µg/kg monthly given for 2 years has been reported to reduce worm burdens by 65% as compared with untreated cats (Guerrero et al, 2002). Because most cats have small worm burdens, it is not worm mass alone that is problematic but the “anaphylactic” type reaction that results when the worms die. This will likely also occur when the ivermectin-treated worms die but the extent of the reaction is unknown.

To date, there are no studies that indicate any form of medical adulticidal therapy increases the survival rate of cats harboring adult heartworms.

Surgical Options

In principle, it is preferable to remove heartworms rather than destroy them *in situ*. This can be accomplished successfully by introducing brush strings, basket catheters (Venco et al, 1998b), basket catheters (Borgarelli et al, 1997), or loop snares via right jugular venotomy or, after left thoracotomy, alligator forceps can be inserted through a right ventricular purse-string incision (Glaus et al, 1995; Rawlings et al, 1994). Before attempting either approach, heartworms should be identified ultrasonographically in locations that can be reached with these inflexible instruments (Borgarelli et al, 1997). When probing from the right jugular vein, worms must be present within the cavae or right atrium because achieving access to the right ventricle is difficult with these instruments. Both atria and ventricles as well as the main pulmonary

artery can be reached through a ventriculotomy incision with straight alligator forceps.

Although it may not be possible to retrieve every worm, the surgical option may be a reasonable alternative to symptomatic support or adulticide treatment of cats that are heavily infected and/or in critical condition (Rawlings et al, 1994). Surgery is specifically indicated in those few cases that develop the caval syndrome. Care must be taken to remove the worms intact because partial or complete traumatic transection of a worm may result in acute circulatory collapse and death (Vencko et al, 1998a).

Additional Considerations for Adulticide Therapy

Wolbachia

Most filarial nematodes, including *D immitis*, harbor obligate, intracellular, gram-negative bacteria belonging to the genus *Wolbachia* (*Rickettsiales*) (Taylor et al, 2005; Kozek, 2005). In infections with other filarial parasites, treatment with tetracyclines during the first month of infection was lethal to some *Wolbachia*-harboring filariae, but not to filariae that did not harbor *Wolbachia*, and treatment of *Wolbachia*-harboring filariae suppressed microfilaremia (Bosshardt et al, 1993; Hoerauf et al, 1999). Similar prophylaxis studies with *D immitis* have been reported (McCall et al, 2011). In one study, tetracycline treatment of heartworm-infected dogs resulted in infertility in the female worms (Bazzocchi et al, 2008). These bacteria also have been implicated in the pathogenesis of filarial diseases, possibly through their endotoxins (Bouchery et al, 2013 ; Kramer et al, 2005). Recent studies have shown that a major surface protein of *Wolbachia* (WSP) induces a specific IgG response in hosts infected by *D immitis* (Kramer et al, 2005). It is hypothesized that *Wolbachia* contributes to pulmonary and renal inflammation through its surface protein WSP, independently from its endotoxin component. Studies to determine the effects of suppressing *Wolbachia* populations with doxycycline prior to adulticide therapy are in progress to determine the clinical utility of this therapeutic approach.

Surveillance of Infected Cats

Serologic retesting at 6- to 12-month intervals for the purpose of monitoring infection status is recommended for all infected cats whether or not they have clinical signs that are treated empirically or are given medical/surgical adulticide therapy. Once adult heartworm infection has been diagnosed, monitoring will be most informative if both antibody

and antigen testing are performed. The retesting interval should be consistent with the clinical circumstances. For asymptomatic cats, an annual retest may be adequate. Spontaneous or adulticide-induced elimination of infection in antigen-positive cats ordinarily will be followed within 4 to 5 months by disappearance of detectable antigenemia (Levy et al, 2003). Once cats become antigen negative and are clinically normal, further antibody retesting becomes optional because antibodies may persist for an indefinite period after the parasites are gone and because continued exposure, even with preventive therapy, will result in a positive test. Radiography and ultrasonography also may be very useful for monitoring the course of infection and disease in those cats with pulmonary vascular and/or parenchymal lung disease, or in which heartworms have been identified with echocardiography.

PREVENTION

Monthly chemoprophylaxis is a safe and effective option for cats living in areas where heartworm infection is considered endemic in dogs and exposure to infective mosquitoes is possible. Many cats live more sheltered lives than do most dogs and are often confined indoors. Unless the home environment provides an effective barrier to the entrance of mosquitoes, these so-called “indoor” cats also may be at risk. In one retrospective study, approximately 25% of cats diagnosed with adult heartworms were considered indoor cats (Atkins et al, 2000). Caregivers should be advised objectively of the potential risk of heartworm infection in their community and for their cat’s living conditions. When monthly heartworm chemoprophylaxis is elected, it should at least be administered within 30 days following the estimated seasonal onset of transmission and be continued within 30 days after that period has ended. Administering a preventive year-round also has merit for the following reasons: 1) activity against some common intestinal parasites (Arther et al, 2005; Bishop et al, 2000; Bowman et al, 1991; Humbert-Droz et al, 2004; Nolan et al, 1992) and in the case of selamectin (Boy et al, 2000) and topical moxidectin + imidacloprid (Arther et al, 2003), external parasites; 2) increased compliance, and 3) retroactive efficacy as a safeguard for inadvertent missed doses. (For a more detailed explanation, consult the Canine Guidelines under the heading Macrocytic Lactones.)

Drugs

Heartworm chemoprophylaxis can be achieved

in cats with monthly doses of either ivermectin or milbemycin oxime orally, or topical moxidectin or selamectin. Preventives should be started in kittens at 8 weeks of age and be administered to all cats in heartworm endemic areas during the heartworm transmission season. The individual minimum monthly prophylactic dose of ivermectin is 24 µg/kg (Longhofer et al, 1995), milbemycin oxime 2.0 mg/kg (Genchi et al, 2004), moxidectin 1.0 mg/kg (Arther et al, 2003), and selamectin 6 mg/kg of body weight (McTier et al, 2000). Administration of these drugs in cats is not precluded by antibody or antigen seropositivity.

Serologic Testing

Seroepidemiologic data for most communities is presently meager; thus, it behooves veterinarians to become familiar with the local risk potential by testing cats before initiating heartworm chemoprophylaxis. While guidelines are still being developed and evaluated, it is considered prudent to establish this serologic benchmark for future reference, in the event it becomes necessary to retest a cat receiving chemoprophylaxis.

Although testing cats before starting chemoprophylaxis is recommended, there is less utility in doing so than is the case for dogs. This apparent contradiction reflects the differences in testing methods and test performance in the two hosts. Pretesting (screening) dogs is limited to documenting either heartworm antigenemia or circulating microfilariae, both of which are specific indicators of adult worm infection in a host that is significantly more likely to become infected. Many, if not most, cats that are antibody positive have only

been transiently infected to the fourth larval stage (Levy et al, 2003). Evidence of exposure of a cat to at least fourth-stage larvae confirms the potential risk of developing heartworm-associated respiratory disease (HARD) and reinforces justification for recommending chemoprophylaxis (Dillon et al, 2014). The use of an antigen test to screen healthy cats is also an option if one is fully aware of its limitations. (Refer to Table 1 in Diagnostic Testing section for limitations of both antibody and antigen test.) The preferred method for screening, however, includes the use of both an antigen and an antibody test.

Since microfilaremia in cats is uncommon, transient, and below concentration levels that might trigger an adverse reaction to microfilaricidal chemoprophylactic drugs, pretesting for microfilariae is unnecessary. Furthermore, antibody retesting of cats already committed to chemoprophylaxis provides no assurance of efficacy because sensitization from repetitive aborted precardiac larval infections is possible in cats that are repetitively exposed (Donoghue et al, 1998). Therefore, the primary reasons for heartworm testing in cats are:

1. To establish an etiologic diagnosis in those individuals that, based on other clinical evidence, are suspected of being infected;
2. To monitor the clinical course of those cats that have already been diagnosed with feline heartworm disease;
3. To establish a baseline reference prior to initiating chemoprophylaxis.

REFERENCES

- Arther RG, Bowmann DD, McCall JW, et al. Feline Advantage Heart™ (imidacloprid and moxidectin) topical solution as monthly treatment for prevention of heartworm infection (*Dirofilaria immitis*) and control of fleas (*Ctenocephalides felis*) on cats. *Parasitol Res.* 2003;90:S137-S139.
- Arther RG, Charles S, Ciszewski DK, et al. Imidacloprid/moxidectin topical solution for the prevention of heartworm disease and the treatment and control of flea and intestinal nematodes of cats. *Vet Parasitol.* 2005;133:219-225.
- Atkins CE, Arther RG, et al. Echocardiographic quantification of *Dirofilaria immitis* in experimentally infected cats. *Vet Parasitol.* 2008;158(3):164-170.
- Atkins CE, DeFrancesco TC, Coats JR, et al. Heartworm infection in cats: 50 cases (1985-1997). *J Am Vet Med Assoc.* 2000;217:355-358.
- Atkins CE, DeFrancesco TC, Miller MW, et al. Prevalence of heartworm infection in cats with signs of cardiorespiratory abnormalities. *J Am Vet Med Assoc.* 1988;212:517-520.
- Bazzocchi C, Mortarino M, Grandi G, et al. Combined ivermectin and doxycycline treatment has microfilaricidal and adulticidal activity against *Dirofilaria immitis* in experimentally infected dogs. *Int J Parasitol.* 2008;38:1401-1410.
- Benedict MQ, Levine RS, Hawley WA, Lounibos LP. Spread of the tiger: global risk of invasion by the mosquito *Aedes albopictus*. *Vector Borne Zoonotic Dis.* 2007;7:76-85.
- Berdoulay P, Levy JK, Snyder PS, et al. Comparison of serological tests for the detection of natural heartworm infection in cats. *J Am Anim Hosp Assoc.* 2004;40:376-384.
- Bestul KJ, McCall JW, Supakorndej N, et al. Evaluation of the ASSURE/FH antibody assay for the detection of feline heartworm infection. In *Recent Advances in Heartworm Disease: Symposium '98*, Tampa, FL. American Heartworm Society, 1998, pp 179-185.
- Bishop BF, Bruce CI, Evans NA, et al. Selamectin: a novel broad-spectrum endectocide for dogs and cats. *Vet Parasitol.* 2000; 91:163-176.
- Blagburn BL, Dillon AR. Feline heartworm disease: solving the puzzle. *Vet Med.* 2007;102 (suppl), 7-14.
- Blagburn BL, Dillon AR, Arther RG, et al. Comparative efficacy of four commercially available heartworm preventive products against the MP3 laboratory strain of *Dirofilaria immitis*. *Vet Parasitol.* 2011;176:189-194.
- Borgarelli M, Venco L, Piga PM, et al. Surgical removal of heartworms from the right atrium of a cat. *J Am Vet Med Assoc.* 1997;211:68-69.
- Bosshardt SC, McCall JW, Coleman SU, et al. Prophylactic activity of tetracycline against *Brugia pahangi* infection in jirds (*Meriones unguiculatus*). *J Parasitol.* 1993;79:775-777.
- Bouchery T, Lefoulon E, Karadjian G, et al. The symbiotic role of *Wolbachia* in Onchocercidae and its impact on filariasis. *Clin Microbiol Infect.* 2013;19:131-140.
- Boudreaux M, Dillon AR, Ravis WR, et al. Effects of treatment with aspirin or aspirin/dipyridamole combination in heartworm negative, heartworm infected, and embolized heartworm-infected dogs. *Am J Vet Res.* 1991;52(12):1992-1999.
- Bowman DD, Atkins CE. Heartworm biology, treatment, and control. *Vet Clin North Am Small Anim Pract.* 2009;39:1127-1158.
- Bowman DD, Johnson RD, Fogelson M, Hepler DI. Effects of milbemyacin oxime on adult ascarids (*Toxocara cati*) in cats with naturally acquired infections. In *Proceedings of the 36th Annual AAVP Meeting*, 1991.
- Boy MG, Six RH, Thomas CA, et al. Efficacy and safety of selamectin against fleas and heartworms in dogs and cats presented as veterinary patients in North America. *Vet Parasitol.* 2000;91:233-250.

- Brawner WR Jr, Dillon AR, Robertson-Plouch CK, Guerrero J. Radiographic diagnosis of feline heartworm disease and correlation to other clinical criteria: Results of a multicenter clinical case study. In *Recent Advances in Heartworm Disease: Symposium '98*, Tampa, FL. American Heartworm Society, 1998, pp 91-95.
- Browne LE, Carter TD, Levy JK, et al. Pulmonary arterial disease in cats seropositive for *Dirofilaria immitis* but lacking adult heartworms in the heart and lungs. *Am J Vet Res*. 2005;66:1544-1549.
- Christensen BM, Hollander AL. Effect of temperature on vector parasite relationships of *Aedes trivittatus* and *Dirofilaria immitis*. *Proc Helminthol Soc Washington*. 1978;45:115-119.
- Christensen BM, Rowley WA. Observations on the laboratory biology and maintenance of *Aedes trivittatus*. *Mosquito News*. 1978;38:9-14.
- Darsie R Jr, Ward R. *Identification and Geographical Distribution of the Mosquitoes of North America, North of Mexico*. University Press of Florida, Gainesville, FL, 2005.
- DeFrancesco TC, Atkins CE. The utility of echocardiography in the diagnosis of feline heartworm disease: A review of published reports. In *Recent Advances in Heartworm Disease: Symposium '98*, Tampa, FL. American Heartworm Society, 1998, pp 103-105.
- DeFrancesco TC, Atkins CE, Miller MW, et al. Use of echocardiography for the diagnosis of heartworm disease in cats: 43 cases (1985-1997). *J Am Vet Med Assoc*. 2001;218:66-69.
- Di Sacco B, Cancrini G, Genchi C. Studio del tropismo nei riguardi del cane e del gatto da parte dei ditteri potenziali vettori delle filariosi in provincia di Pavia. *Parassitologia*. 1992;34:11-12.
- Dillon AR. Feline dirofilariasis. *Vet Clin North Am Small Anim Pract*. 1984;14:1185-1199.
- Dillon AR. Clinical significance of feline heartworm disease. *Vet Clin North Am Small Anim Pract*. 1998;28:1547-1565.
- Dillon AR, Atkins C, Clekis T, et al. Feline heartworm disease, Part 1. *Feline Pract*. 1996;24:12-16.
- Dillon AR, Atkins C, Clekis T, et al. Feline heartworm disease, Part 2. *Feline Pract*. 1997a;25:26-30.
- Dillon AR, Atkins C, Clekis T, et al. Feline heartworm disease, Part 3. *Feline Pract*. 1997b;25:12-21.
- Dillon AR, Blagburn B, Tillson DM, et al. Immature heartworm infection produces pulmonary parenchymal, airway, and vascular disease in cats. *J Vet Intern Med*. 2007;21:608-609.
- Dillon AR, Brawner WR, Robertson-Plough CK, Guerrero J. Feline heartworm disease: Correlation of clinical signs, serology, and other diagnostics. Results of a multicenter study. In *Recent Advances in Heartworm Disease: Symposium '98*, American Heartworm Society, Tampa, FL. 1998:153-158
- Dillon AR, Tillson DM, Hathcock J et al. Lung histopathology, radiography, high-resolution computed tomography, and bronchio-alveolar lavage cytology are altered by *Toxocara cati* infection in cats and is independent of development of adult intestinal parasites. *Vet Parasitol*. 2013;193:413-426.
- Dillon AR, Tillson DM, Wooldridge A, et al. Effect of pre-cardiac and adult stages of *Dirofilaria immitis* in pulmonary disease in cats: CBC, bronchial lavage cytology, serology, radiographs, CT images, bronchial reactivity, an histopathology. *Vet Parasitol*. 2014;206:24-37.
- Dillon AR, Warner AE, Brawner W, et al. Activity of pulmonary intravascular macrophages in cats and dogs with and without adult *Dirofilaria immitis*. *Vet Parasitol*. 2008;158(3):171-176.
- Dillon AR, Warner AE, Molina RM. Pulmonary parenchymal changes in dogs and cats after experimental transplantation of dead *Dirofilaria immitis*. In *Proceedings of the Heartworm Symposium '95*, Auburn, AL. American Heartworm Society, 1995, pp 97-101.
- Donahoe JM, Kneller SK, Lewis RE. Hematologic and radiographic changes in cats after inoculation with infective larvae of *Dirofilaria immitis*. *J Am Vet Med Assoc*. 1976a;168:413-417.

- Donahoe JM, Kneller SK, Lewis RE. In vivo pulmonary arteriography in cats infected with *Dirofilaria immitis*. *Vet Radiol*. 1976b;17:147-151.
- Donoghue AR, Piché CA, Radecki SV, et al. Effect of prophylaxis on anti heartworm antibody levels in cats receiving trickle experimental infections of *Dirofilaria immitis*. In *Recent Advances in Heartworm Disease: Symposium '98*, Tampa, FL. American Heartworm Society, 1998, pp 135-138.
- Ernst J, Slocombe JOD. The effect of low temperature on developing *Dirofilaria immitis* larvae in *Aedes triseriatus*. In *Proceedings of the Heartworm Symposium '83*, Orlando, FL. American Heartworm Society, 1983, pp 1-4.
- Fernandez C, Chikweto A, Mofya S, et al. A serological study of *Dirofilaria immitis* in feral cats in Grenada, West Indies. *J Helminthol*. 2010;84:390-393.
- Fortin JF, Slocombe JOD. Temperature requirements for the development of *Dirofilaria immitis* in *Aedes triseriatus* and *Ae. vexans*. *Mosquito News*. 1981;41:625-633.
- Genchi C, Cody R, Pengo G, et al. Efficacy of a single milbemycin oxime administration in combination with praziquantel against experimentally induced heartworm (*Dirofilaria immitis*) infection in cats. *Vet Parasitol*. 2004;122:287-292.
- Genchi C, Di Sacco B, Cancrini G. Epizootology of canine and feline heartworm infection in Northern Italy: possible mosquito vectors. In *Proceedings of the Heartworm Symposium '92*, Austin, TX. American Heartworm Society, 1992a, pp 39-46.
- Genchi C, Guerrero J, Di Sacco B, Formaggini L. Prevalence of *Dirofilaria immitis* infection in Italian cats. In *Proceedings of Heartworm Symposium '92*, Austin, TX. American Heartworm Society, 1992b, pp 97-102.
- Genchi C, Kramer L, Venco L, et al. Comparison of antibody and antigen testing with echocardiography for the detection of heartworm (*Dirofilaria immitis*) in cats. In *Recent Advances in Heartworm Disease: Symposium '98*, Tampa, FL. American Heartworm Society, 1998, pp 173-177.
- Genchi C, Venco L, Ferrari N, et al. Feline heartworm (*Dirofilaria immitis*) infection: a statistical elaboration of the duration of the infection and life expectancy in asymptomatic cats. *Vet Parasitol*. 2008;158:177-182.
- Genchi C, Venco L, Magnino S, et al. Aggiornamento epidemiologico sulla filariosi del cane e del gatto. *Veterinaria*. 1993;7:5-11.
- Gjullin CM, Yates WW, Stage HH. Studies on *Aedes vexans* (Meig.) and *Aedes sticticus* (Meig.) floodwater mosquitoes in the lower Columbia River Valley. *Ann Entomol Soc Am*. 1950;43: 262-275.
- Glaus TM, Jacobs GJ, Rawlings CA, et al. Surgical removal of heartworms from a cat with caval syndrome. *J Am Vet Med Assoc*. 1995;206:663-666.
- González-Miguel J, Morchón R, et al. Identification of *Dirofilaria immitis* immunoreactive proteins recognized by sera from infected cats using two-dimensional electrophoresis and mass spectrometry. *Mol Biochem Parasitol*. 2010;174:78-82.
- Goodman DA. Evaluation of a single dose of melarsomine dihydrochloride for adulticidal activity against *Dirofilaria immitis* in cats. Thesis for Master of Science Degree. University of Georgia, Athens, GA, 1996.
- Guerrero J, McCall JW, Dzimianski MT, et al. Prevalence of *Dirofilaria immitis* infection in cats from the southeastern United States. In *Proceedings of the American Heartworm Symposium '92*, Austin, TX. American Heartworm Society, 1992, pp 92-95.
- Guerrero J, McCall JW, Genchi C. The use of macrocyclic lactones in the control and prevention of heartworm and other parasites in dogs and cats. In Vercruysse J, Rew RS (eds): *Macrocyclic Lactones in Antiparasitic Therapy*. Wallingford, UK: CABI Publishing, 2002, pp 353-369.
- Guerrero J, McCall JW, Genchi C, et al. Recent advances in heartworm disease. *Vet Parasitol*. 2004;125:105-130.

- Hinman EH, Hurlbut HS. A study of winter activities and hibernation of *Anopheles quadrimaculatus* in the Tennessee Valley. *Am J Trop Med Hyg.* 1940;20:431-446.
- Hoerauf A, Nissen-Pahle K, Schmetz C, et al. Tetracycline therapy targets intracellular bacteria in the filarial nematode *Litomosoides sigmodontis* and results in filarial infertility. *J Clin Invest.* 1999;103:11-18.
- Holmes RA, Clark JN, et al. Histopathologic and radiographic studies of the development of heartworm pulmonary vascular disease in experimentally infected cats. In *Proceedings of the Heartworm Symposium '92.* Austin, TX. American Heartworm Society, 1992, pp 81-89.
- Humbert-Droz E, Buscher G, Cavalleri D, Junquera P. Efficacy of milbemycin oxime against fourth-stage larvae and adults of *Ancylostoma tubaeforme* in experimentally infected cats. *Vet Rec.* 2004;154:140-143.
- Knight DH, Lok JB. Seasonality of heartworm infection and implications for chemoprophylaxis. *Clin Tech Small Anim Pract.* 1998;13:77-82.
- Kozek WJ. What is new in the *Wolbachia/Dirofilaria* interaction. *Vet Parasitol.* 2005;133(2-3):127-132.
- Kozek WJ, Vazquez AE, Gonzalez C Jr, et al. Prevalence of canine filariae in Puerto Rico and the Caribbean. In *Proceedings of the Heartworm Symposium '95,* Auburn, AL. American Heartworm Society, 1995.
- Kramer L, Genchi C. Feline heartworm infection: serological survey of asymptomatic cats living in northern Italy. *Vet Parasitol.* 2002;104:43-50.
- Kramer L, Simon F, Tamarozzi F, et al. Is *Wolbachia* complicating the pathological effects of *Dirofilaria immitis* infections? *Vet Parasitol.* 2005;133(2-3):133-136.
- Kramer LH, Tamarozzi F, Morchón R, et al. Immune response to and tissue localization of the *Wolbachia* surface protein (WSP) in dogs with natural heartworm (*Dirofilaria immitis*) infection. *Vet Immunol Immunopathol.* 2005;106:303-308.
- Lee ACY, Atkins CE. Understanding Feline heartworm infection: Disease, diagnosis, and treatment. *Top Comp Anim Med.* 2010;25:224-230.
- Levy JK. Diagnostic changes in feline heartworm disease. In *State of the Heartworm '07 Symposium,* Washington, DC. American Heartworm Society, 2007, p 30.
- Levy JK, Lappin MR, Crawford PC, Glaser AL. Infectious diseases of dogs and cats rescued from the 2005 Gulf Coast hurricane disaster. In *Research Abstract Program of the 25th Annual ACVIM Forum,* Abstract #19, p 577, 2007.
- Levy JK, Lappin MR, Glaser AL, et al. Prevalence of infectious diseases in cats and dogs rescued following Hurricane Katrina. *J Am Vet Med Assoc.* 2011;238(3):311-317.
- Levy JK, Snyder PS, Taveres LM, et al. Prevalence and risk factors for heartworm infection in cats from northern Florida. *J Am Anim Hosp Assoc.* 2003;39:533-537.
- Little SE, Raymond MR, Thomas JE, et al. Heat treatment prior to testing allows detection of antigen of *Dirofilaria immitis* in feline serum. *Parasites Vectors.* 2014;7:1.
- Lok JB, Knight DH. Laboratory verification of a seasonal heartworm transmission model. In *Recent Advances in Heartworm Disease: Symposium '98,* Tampa, FL. American Heartworm Society, 1998, pp 15-20.
- Longhofer SL, Daurio CP, Plue RE, et al. Ivermectin for the prevention of feline heartworm disease. In *Proceedings of the Heartworm Symposium '95,* Auburn, AL. American Heartworm Society, 1995, pp 177-182.
- Löwenberg Neto P, Navarro-Silva MA. Development, longevity, gonotrophic cycle and oviposition of *Aedes albopictus* Skuse (Diptera: Culicidae) under cyclic temperatures. *Neotrop Entomol.* 2004;33:29-33.
- Ludlam KW, Jachowski LA Jr, Otto GF. Potential vectors of *Dirofilaria immitis*. *J Am Vet Med Assoc.* 1970;157:1354-1359.

- Mackenzie A. Pathological changes in lungworm infestation in two cats with special reference to changes in pulmonary arterial branches. *Res Vet Sci.* 1960;1:255-259.
- McCall JW. Evaluation of feline heartworm antibody test kits and diagnostic laboratory test. In *Recent Advances in Heartworm Disease: Symposium '01*. American Heartworm Society, 2001, pp 125-134.
- McCall JW, Dzimianski MT, McTier TL, et al. Biology of experimental heartworm infections in cats. In *Proceedings of the American Heartworm Symposium '92*, Austin, TX. American Heartworm Society, 1992, pp 71-79.
- McCall JW, Genchi C, Kramer LH, et al. Heartworm disease in animals and humans. In Rollinson D, Hay SI (eds): *Advances in Parasitology*. New York: Academic Press, 2008, pp 193-285.
- McCall JW, Guerrero J, Supakorndej P. Evaluation of the accuracy of antigen and antibody tests for detection of heartworm infection in cats. In *Recent Advances in Heartworm Disease: Symposium '98*, Tampa, FL. American Heartworm Society, 1998, p 32.
- McCall JW, Kramer L, Genchi C, et al. Effects of doxycycline on early infections of *Dirofilaria immitis* in dogs. *Vet Parasitol.* 2011;176:361-367.
- McCall JW, Supakorndej N, Ryan W, Soll MD. Utility of an ELISA-based antibody test for detection of heartworm infection in cats. In *Proceedings of the Heartworm Symposium '95*, Auburn, AL. American Heartworm Society, 1995, pp 127-133.
- McLeroy LW. Evaluation of melarsomine dihydrochloride for adulticidal activity against *Dirofilaria immitis* in cats with intravenously transplanted adult heartworms. Thesis for Master of Science Degree. University of Georgia, Athens, GA, 1998.
- McTier TL, McCall JW, Dzimianski MT, et al. Prevention of heartworm infection in cats by treatment with ivermectin at one month post-infection. In *Proceedings of the Heartworm Symposium '92*, Austin, TX. American Heartworm Society, 1992, pp 111-116.
- McTier TL, Shanks DJ, Watson P, et al. Prevention of experimentally induced heartworm (*Dirofilaria immitis*) infections in dogs and cats with a single topical application of selamectin. *Vet Parasitol.* 2000;91:259-268.
- Miller MW, Atkins CE, Stemme K, et al. Prevalence of exposure to *Dirofilaria immitis* in cats in multiple areas of the United States. In *Recent Advances in Heartworm Disease: Symposium '98*, Tampa, FL. American Heartworm Society, 1998, pp 161-166.
- Morchón R, Carretón E, González Miguel J, Mellado Hernández I. Heartworm disease (*Dirofilaria immitis*) and their vectors in Europe. New distribution trends. *Front Physiol.* 2012;3.
- Nelson CT, Self TS. Incidence of *Dirofilaria immitis* in shelter cats in southeast Texas. In *Recent Advances in Heartworm Disease: Symposium '98*, Tampa, FL. American Heartworm Society, 1998, pp 63-66.
- Nelson CT, Seward RL, McCall JW, et al. Guidelines for the Diagnosis, Prevention, and Management of Heartworm (*Dirofilaria immitis*) Infection in Cats. American Heartworm Society, 2007.
- Nolan TJ, Niamatali S, Bhopale V, et al. Efficacy of a chewable formulation of ivermectin against a mixed infection of *Ancylostoma braziliense* and *Ancylostoma tubaeforme* in cats. *Am J Vet Res.* 1992;53:1411-1413.
- Piché CA, Cavanaugh MT, Donoghue AR, et al. Results of antibody and antigen testing for feline heartworm infection at Heska® Veterinary Diagnostic Laboratories. In *Recent Advances in Heartworm Disease: Symposium '98*, Tampa, FL. American Heartworm Society, 1998, pp 139-143.
- Pratt HD, Moore CD. *Mosquitoes of Public Health Importance and Their Control*. United States Government Printing Office, Washington, DC, 1960.
- Rawlings CA. Pulmonary arteriography and hemodynamics during feline heartworm disease. Effect of aspirin. *J Vet Intern Med.* 1990;4:285-291.

- Rawlings CA, Calvert CA, Glaus TM, Jacobs GJ. Surgical removal of heartworms. *Sem Vet Med Surg Small Anim.* 1994;9:200-205.
- Ryan WG, Gross SJ, Soll MD. Diagnosis of feline heartworm infection. In *Proceedings of the Heartworm Symposium '95*, Auburn, AL. American Heartworm Society, 1995, pp 121-126.
- Ryan WG, Newcomb KM. Prevalence of feline heartworm disease—a global review. In *Proceedings of the Heartworm Symposium '95*, Auburn, AL. American Heartworm Society, 1995, pp 79-86.
- Schafer M, Berry CR. Cardiac and pulmonary artery mensuration in feline heartworm disease. *Vet Radiol Ultrasound.* 1995;36:499-505.
- Scoles GA, Dickson SL. New foci of canine heartworm associated with introductions of new vector species. In *Proceedings of the Heartworm Symposium '95*, Auburn, AL. American Heartworm Society, 1995, pp 27-35.
- Scoles GA, Dickson SL, Blackmore MS. Assessment of *Aedes sierrensis* as a vector of canine heartworm in Utah using a new technique for determining the infectivity rate. *J Am Mosq Control Assoc.* 1993;9:88-90.
- Selcer BA, Newell SM, Mansour AE, McCall JW. Radiographic and 2-D echocardiographic findings in eighteen cats experimentally exposed to *D. immitis* via mosquito bites. *Vet Radiol Ultrasound.* 1996;37:37-44.
- Simón F, Genchi C, Prieto G, Allende E. Immunity in the vertebrate hosts. In Simón F, Genchi C (eds): *Heartworm Infection in Humans and Animals*. Ediciones Universidad de Salamanca, Salamanca, Spain, 2001, p 218.
- Slocombe J, Srivastava B, Surgeoner G. The transmission period for heartworm in Canada. In *Proceedings of the Heartworm Symposium '95*, Auburn, AL. American Heartworm Society, 1995, pp 43-48.
- Snyder PS, Levy JK, Salute ME, et al. Performance of serologic tests used to detect heartworm infection in cats. *J Am Vet Med Assoc.* 2000;216:693-700.
- Stewart VA, Hepler DI, Grieve RB. Efficacy of milbemycin oxime in chemoprophylaxis of dirofilariasis in cats. *Am J Vet Res.* 1992;53:2274-2277.
- Swerczek TW, Nielsen SW, Helmboldt CF. Ascariasis causing pulmonary arterial hyperplasia in cats. *Res Vet Sci.* 1970;11:103-104.
- Taylor MJ, Bandi C, Hoerauf A. *Wolbachia* bacterial endosymbionts of filarial nematodes. *Adv Parasitol.* 2005;60:245-284.
- Terrell S. Heartworm in Alaska: Prevalence in domestic dogs and wild canids. In *Recent Advances in Heartworm Disease: Symposium '98*, Tampa, FL. American Heartworm Society, 1998, pp 83-86.
- Venco L, Borgarelli M, Ferrari E, et al. Surgical removal of heartworms from naturally-infected cats. In *Recent Advances in Heartworm Disease: Symposium '98*, Tampa, FL. American Heartworm Society, 1998a, pp 241-246.
- Venco L, Morini S, Ferrari E, Genchi C. Technique for identifying heartworms in cats by 2-D echocardiography. In *Recent Advances in Heartworm Disease: Symposium '98*, Tampa, FL. American Heartworm Society, 1998b, pp 97-102.



**AMERICAN
HEARTWORM
SOCIETY™**
EST.1974

These guidelines are based on the latest information on heartworm disease. In keeping with the objective of the Society to encourage adoption of standardized procedures for the diagnosis, treatment, and prevention of heartworm disease, they will continue to be updated as new knowledge becomes available.